

## ORIGINAL PAPER

# EXPRESSION AND CLINICAL SIGNIFICANCE OF KDM5A, KDM5B, AND FOXO1 IN ENDOMETRIAL CANCER

YAO GAO<sup>1</sup>, JUN GAO<sup>2</sup>

<sup>1</sup>Department of Obstetrics and Gynecology, Suzhou Hospital, Affiliated Hospital of Medical School, Nanjing University, Suzhou, China

<sup>2</sup>Department of Obstetrics and Gynecology, Jiangxi Cancer Hospital, The Second Affiliated Hospital of Nanchang Medical College, Jiangxi Clinical Research Center for Cancer, Nanchang, Jiangxi, China

---

There is growing evidence that the KDM5 family of histone demethylases plays a causal role in human cancer. However, few studies have been reported on the KDM5 family in endometrial carcinoma (EC). Moreover, it was found that there was some correlation between the KDM5 family and FOXO1 in EC. The current study was performed to explore the expressions of KDM5A, KDM5B, and FOXO1 in endometrioid adenocarcinoma detected by immunohistochemistry; paracancer endometrium, simple hyperplastic endometrium, and normal endometrium were used as control groups to explore the possible diagnostic value of KDM5A and KDM5B expression in endometrioid adenocarcinoma, with the aim of evaluating the potential of this marker in predicting the prognosis of endometrioid adenocarcinoma.

**Key words:** endometrioid adenocarcinoma, KDM5A, FOXO1, immunohistochemistry.

---

## Introduction

Endometrial carcinoma (EC) is an epithelial malignant tumour originating from endometrial glands. Adenocarcinoma is the most common, accounting for 20–30% of female genital tract malignancies, and its incidence is increasing annually [1]. Oestrogen is a major risk factor for the development of EC, and 5–25% of EC cases are associated with high-risk genetic mutations, especially those affecting the DNA mismatch repair pathway, leading to early onset of the disease [2]. Segmentalisation of hysteroscopy is currently the most reliable method for diagnosing EC [3]. Early detection and appropriate treatment are commonly related to a good prognosis; however, the prognosis of patients with advanced or recurrent EC after standard treatment is not satisfying [4, 5]. Among patients with EC, some are still in the child-bearing age and most have the desire to retain fertility [6]. With the delay of childbearing age

in modern women, the treatment of fertility preservation in EC has attracted increasing attention [7]. With the rapid development of medicine, ‘standardised’ and ‘individualised’ treatment are the 2 most important concepts for the treatment of tumours [8].

The KDM5 family is histone H3K4-specific demethylase. Increasing evidence shows that the histone demethylase KDM5 family plays a causal role in human cancer. Particularly, KDM5A and KDM5B promote the proliferation of cancer cells, reduce the expression of tumour suppressor genes, promote the development of drug tolerance, and maintain the expression of tumour promoter genes [9]. *KDM5A* and *KDM5B* gene amplification have been found in a variety of human cancers [10]. By regulating the oestrogen receptor signalling pathway and reducing cell transcription heterogeneity, the deletion or inhibition of gene *KDM5A/B* can increase the sensitivity against oestrogen, and it is associated with chemotherapy resistance [11]. Therefore, KDM5A and

KDM5B are expected to be new targets for the treatment of malignant tumours.

FOXO1 is a transcription factor and a member of the FOXO subfamily. It is widely found in eukaryotes, and its gene expression varies in time and space. FOXO1 is underexpressed in many cancers because its downstream target genes are regulated to play multiple roles, such as promoting cell apoptosis and inhibiting cell growth, cell cycle, and oxidative stress [12]. FOXO1 may be involved in EC through certain signalling pathways, but the exact mechanism has not been determined.

In this study, immunohistochemistry (IHC) was used to detect the expression of KDM5A, KDM5B and FOXO1 in EC. Differences and correlations of KDM5A, KDM5B, and FOXO1 in EC tissues were statistically analysed to explore their clinical significance in EC tissues and provide new ideas for the study of EC.

## Material and methods

### Patients and samples

Thirty archival wax blocks of tissue specimens diagnosed as endometrioid adenocarcinoma after gynaecological surgery in the Jiangxi Cancer Hospital collected January 2015 – June 2019 were selected as research objects. The median age of the patients was 54.47 years, with 24 postmenopausal patients and 6 premenopausal patients. Inclusion criteria were as follows: complete clinicopathological data, did not undergo preoperative radiotherapy, chemotherapy, and hormone therapy; and no other malignant diseases. Exclusion criteria were as follows: incomplete clinicopathological data; history of surgery, endocrine therapy, chemoradiotherapy, and other treatments; and with severe comorbidities and other malignancies. Additionally, 15 paracarcinoma endometrial specimens morphologically identical to normal endometrial tissues were acquired from within 2 cm of the tumour boundary. Fifteen patients were pathologically confirmed to have simple hyperplastic endometrium, and 15 normal endometria underwent total hysterectomy due to uterine fibroids. The tumour staging was referred to the FIGO-2018 Cancer Report: Guidelines for Diagnosis and Treatment of EC.

### Experimental procedure

Tissue wax blocks meeting the requirements were obtained from the Pathology Department of the Jiangxi Cancer Hospital. The paraffin specimens were sliced continuously with a thickness of 3  $\mu\text{m}$ , and the specimens were placed in an incubator at 80°C for 60 min. The slides were removed for dewaxing with xylene solution, repaired with 40 ml of EDTA antigen repair solution (1 : 100 diluted FOXO1 mono-

clonal antibody, 1 : 400 diluted KDM5A polyclonal antibody and 1 : 500 diluted KDM5B polyclonal antibody), incubated at 37°C for 70 min, and washed with phosphate-buffered saline (PBS) 3 times. Secondary antibody (universal rat/rabbit secondary antibody – horseradish peroxidase polymer) was then dropwise added, and the slides were incubated again at 37°C for 30 min, removed, and rinsed with PBS 3 times for 3 min each time. DAB chromogenic agent at 50–100  $\mu\text{l}$  was then added for staining for 5 min. The slides were rinsed with running tap water, immersed in haematoxylin for 3 min, rinsed, dried, and sealed with neutral resin.

### Evaluation of immunohistochemical staining

In accordance with the results of observation under a microscope, the immunohistochemical scoring criteria were as follows [13]: 5 high-magnification fields (400) were randomly selected under the optical microscope and scored according to the percentage of positive cells. The number of positive cells was 0 points if less than 10%, 1 point if between 10% and 40%, 2 points if between 41% and 70%, and 3 points if more than 70%. Scores according to staining intensity were as follows: unstained – 0 points, light yellow – 1 point, brown yellow – 2 points, and brown – 3 points. The percentage of coloured tumour cells in the visual field at each high magnification was used for observation and scoring. Comprehensive evaluation was expressed as the product of the 2 scoring points. The average value of the 5 visual fields was taken as the final immunohistochemical score: 0–1 was classified as negative, and 2–9 was classified as positive. The results were recorded. Phosphate-buffered saline was used as negative control instead of primary antibody, and the positive slices were used as positive control.

### Follow-up method

Follow-up visits were conducted once every 3–6 months for the first 2–3 years after initial treatment and once every 6–12 months thereafter. Follow-up included questions about the following: possible recurrence symptoms, lifestyle, obesity, and exercise. Patients with elevated CA125 at initial treatment were reviewed at follow-up. Imaging examinations were selected according to clinical indications, such as magnetic resonance imaging computed tomography [1].

### Statistical analysis

SPSS 26.0 statistical software was used for statistical analysis. Multiple independent samples were statistically analysed by the Kruskal-Wallis test, and pairwise comparison between groups was performed by the Game-Howell test. The survival rates were compared by log-rank test, and the Spearman test

was used for protein correlation analysis.  $P < 0.05$  was considered statistically significant. The study was reviewed and approved by the Ethics Committee of Jiangxi Cancer Hospital (Ethics No. 2022ky294).

## Results

### Expression of KDM5A, KDM5B, and FOXO1

Expression of KDM5A, KDM5B, and FOXO1 in normal endometrium, simple hyperplastic endometrium, paracancer of the endometrium, and endometrioid adenocarcinoma.

The expression levels of KDM5A, KDM5B, and FOXO1 in the tissues of the 4 groups were detected by IHC. The results showed that KDM5A was mainly expressed in the nucleus of endometrioid adenocarcinoma tissues, and the other 3 groups were mainly expressed in the cytoplasm; KDM5B was mainly expressed in the cytoplasm of each group; FOXO1 was mainly expressed in the cytoplasm of endometrioid adenocarcinoma tissues; and the other 3 groups were mainly expressed in the nucleus.

#### *Expression of KDM5A in different intima tissues*

The positive expression intensity of KDM5A in each tissue was statistically analysed by Kruskal-Wallis test, and  $H = 17,226$ ,  $p < 0.001$  indicated that the difference was statistically significant. The positive expression of KDM5A in normal endometrial tissues was higher than that in the other 3 groups ( $p < 0.05$ ). The positive expression of KDM5A in simple hyperplastic endometrium, paracarcinoma, and endometrioid adenocarcinoma gradually decreased, but the difference was not statistically significant ( $p > 0.05$ ) (Fig. 1).

#### *Expression of KDM5B in different intima tissues*

The positive expression of KDM5B in each tissue was statistically analysed by Kruskal-Wallis test, and  $H = 26,720$ ,  $p < 0.001$ , indicated that the difference was statistically significant. The positive expression of KDM5B in endometrioid adenocarcinoma was higher than that in the other 3 groups ( $p < 0.05$ ). The positive expression of KDM5B in normal endometrium, paracarcinoma endometrium, and simple hyperplastic endometrium increased gradually, but the difference was not statistically significant ( $p > 0.05$ ) (Fig. 2).

#### *Expression of FOXO1 in different intima tissues*

The positive expression of FOXO1 in each tissue was statistically analysed by Kruskal-Wallis test, and  $H = 26,048$ ,  $p < 0.001$ , indicated that the difference was statistically significant. The positive expression of FOXO1 in normal endometrial tissue was higher

than that in the other 3 groups ( $p < 0.05$ ). No significant difference in the positive expression of FOXO1 was observed among simple hyperplastic endometrium, paracancer endometrium, and endometrioid adenocarcinoma ( $p > 0.05$ ) (Fig. 3).

### Correlation analysis of KDM5A, KDM5B, and FOXO1

#### *Correlation analysis of KDM5A and KDM5B expression in endometrioid adenocarcinoma*

Spearman correlation analysis showed a significant negative correlation between KDM5A and KDM5B expression in endometrioid adenocarcinoma ( $r = -0.709$ ,  $p < 0.001$ ) (Table 1).

#### *Correlation analysis of KDM5A and FOXO1 expression in endometrioid adenocarcinoma*

Spearman correlation analysis showed a significant positive correlation between KDM5A and FOXO1 expression in endometrioid adenocarcinoma ( $r = 0.515$ ,  $p = 0.004$ ) (Table 2).

#### *Correlation analysis of KDM5B and FOXO1 expression in endometrioid adenocarcinoma*

Spearman correlation analysis showed a negative correlation between KDM5B and FOXO1 expression in endometrioid adenocarcinoma ( $r = -0.442$ ,  $p = 0.014$ ) (Table 3).

### Relationship of the expression of KDM5A, KDM5B, and FOXO1 with the prognosis of patients with endometrioid adenocarcinoma

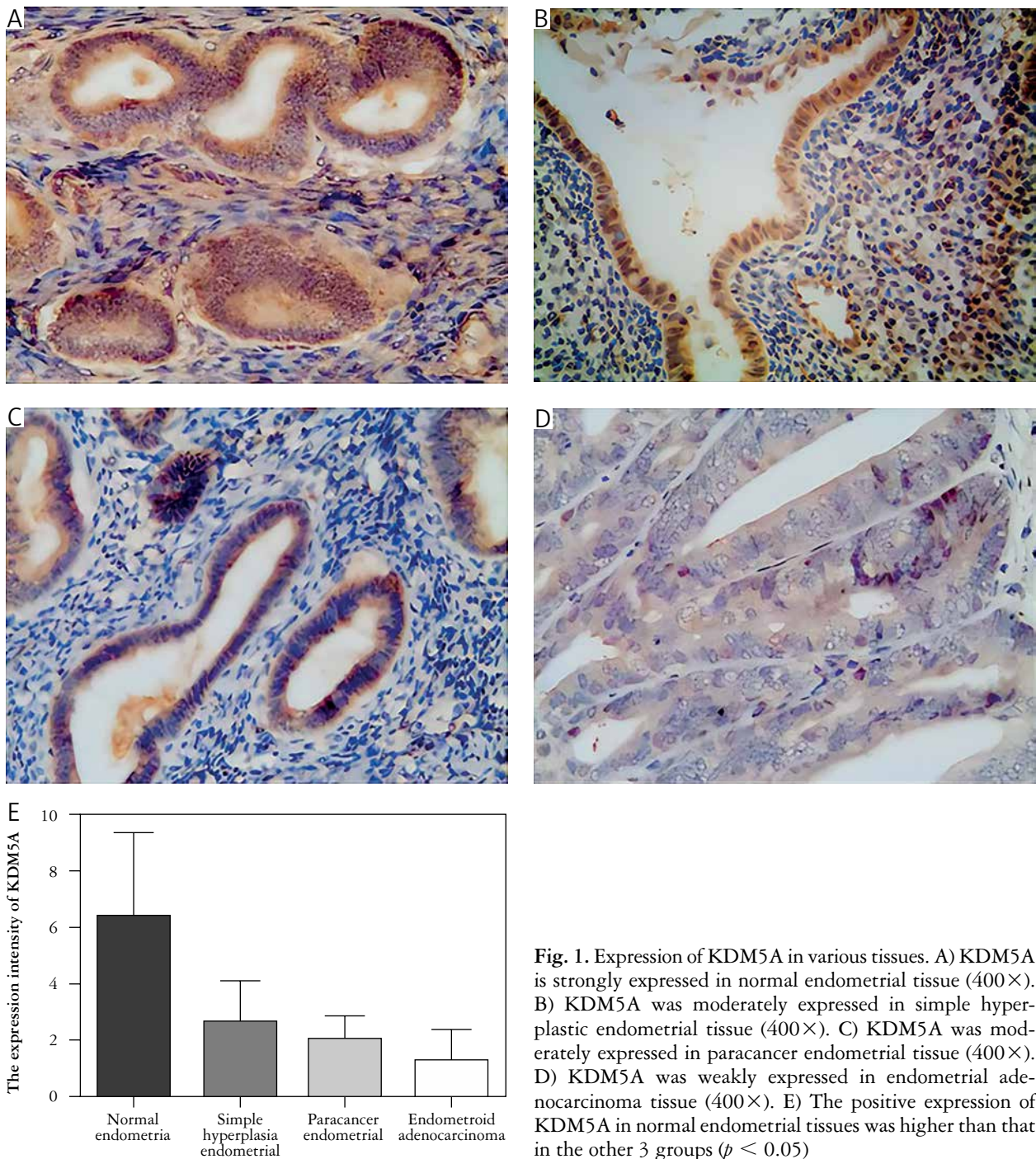
Thirty patients with endometrioid adenocarcinoma were followed up from the date of surgery until March 2020. The follow-up rate was 100% through outpatient and telephone follow-up. The median follow-up time was 31 months (13–49 months) to the end of follow-up. Eight of the patients relapsed or died.

#### *Relationship between KDM5A expression and prognosis of patients with endometrioid adenocarcinoma*

The log-rank test revealed that the estimated average survival time of patients with positive and negative KDM5A expression was 39.385 and 29.034 months, respectively, with no statistically significant difference ( $p = 0.735$ ) (Fig. 4).

#### *Relationship between KDM5B expression and prognosis of patients with endometrioid adenocarcinoma*

The log-rank test revealed that the estimated mean survival time of patients with positive and negative KDM5B expression was 32.733 and 46.465 months, respectively, with statistical significance ( $p = 0.001$ ) (Fig. 5).



**Fig. 1.** Expression of KDM5A in various tissues. A) KDM5A is strongly expressed in normal endometrial tissue (400 $\times$ ). B) KDM5A was moderately expressed in simple hyperplastic endometrial tissue (400 $\times$ ). C) KDM5A was moderately expressed in paracancer endometrial tissue (400 $\times$ ). D) KDM5A was weakly expressed in endometrial adenocarcinoma tissue (400 $\times$ ). E) The positive expression of KDM5A in normal endometrial tissues was higher than that in the other 3 groups ( $p < 0.05$ )

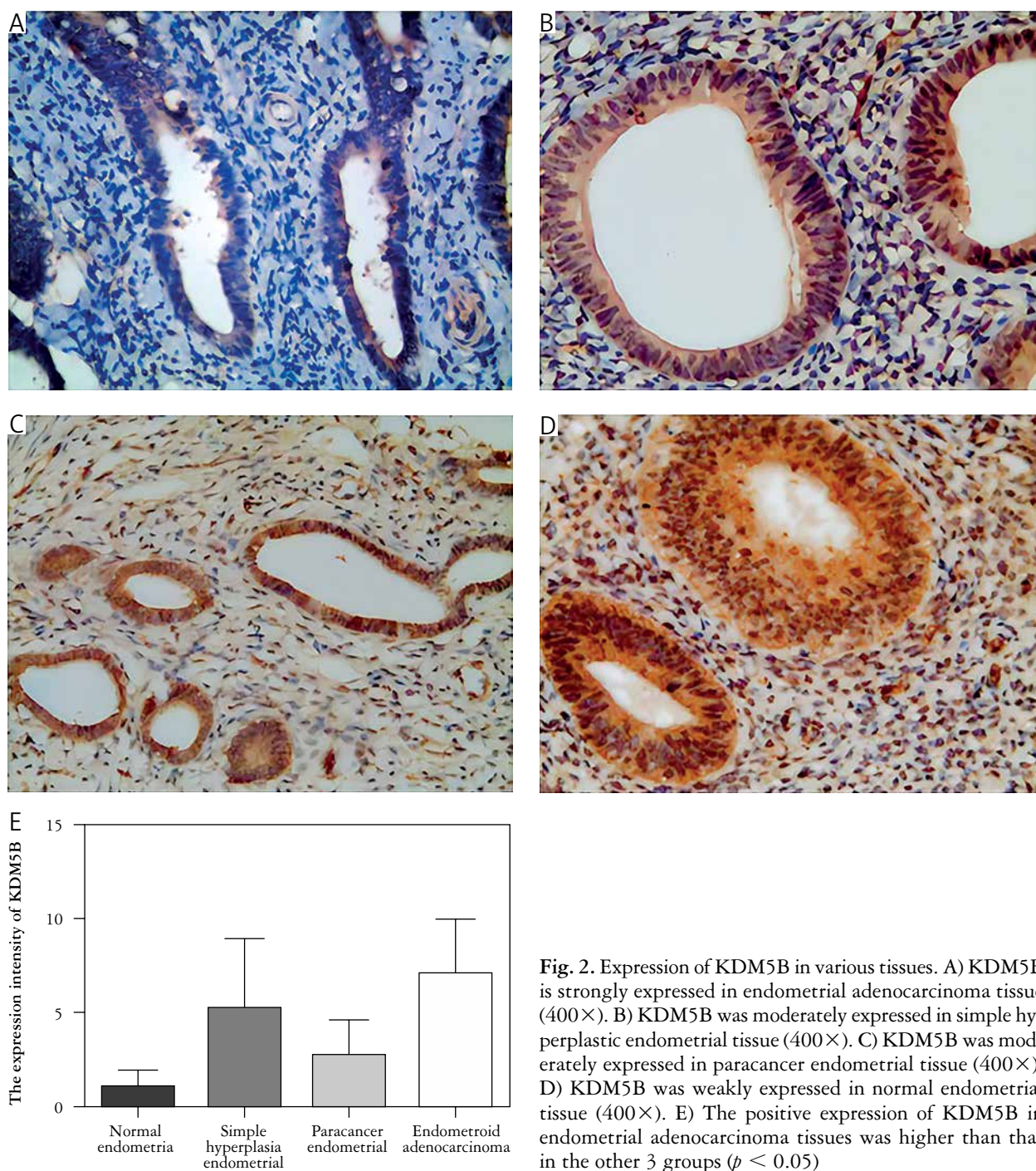
#### *Relationship between FOXO1 expression and prognosis of patients with endometrioid adenocarcinoma*

The log-rank test revealed that the estimated mean survival time of patients with positive and negative FOXO1 expression was 45.597 and 36.016 months, respectively, with no statistical significance ( $p = 0.138$ ) (Fig. 6).

#### **Discussion**

Endometrial carcinoma is one of the 3 major malignant tumours of the female reproductive system.

According to the statistics of the American Cancer Center in 2020, new EC cases accounted for 7% of all female cancers, the death cases accounted for 4%, and the onset age tends to be younger [14]. The main cause of EC is that the endometrium is stimulated by endogenous and exogenous oestrogen for a long time [15]. Oestrogen stimulates endometrial cells for a long time and induces their proliferation, greatly increasing the probability of endometrial lesions [16]. Most EC lesions are confined to the uterine body, and the survival rate of stage I EC is about 80% [17]. Therefore, risk factors for the progression of endometrial hyperplasia to EC must be identified [18]. Various meth-



**Fig. 2.** Expression of KDM5B in various tissues. A) KDM5B is strongly expressed in endometrial adenocarcinoma tissue (400×). B) KDM5B was moderately expressed in simple hyperplastic endometrial tissue (400×). C) KDM5B was moderately expressed in paracancer endometrial tissue (400×). D) KDM5B was weakly expressed in normal endometrial tissue (400×). E) The positive expression of KDM5B in endometrial adenocarcinoma tissues was higher than that in the other 3 groups ( $p < 0.05$ )

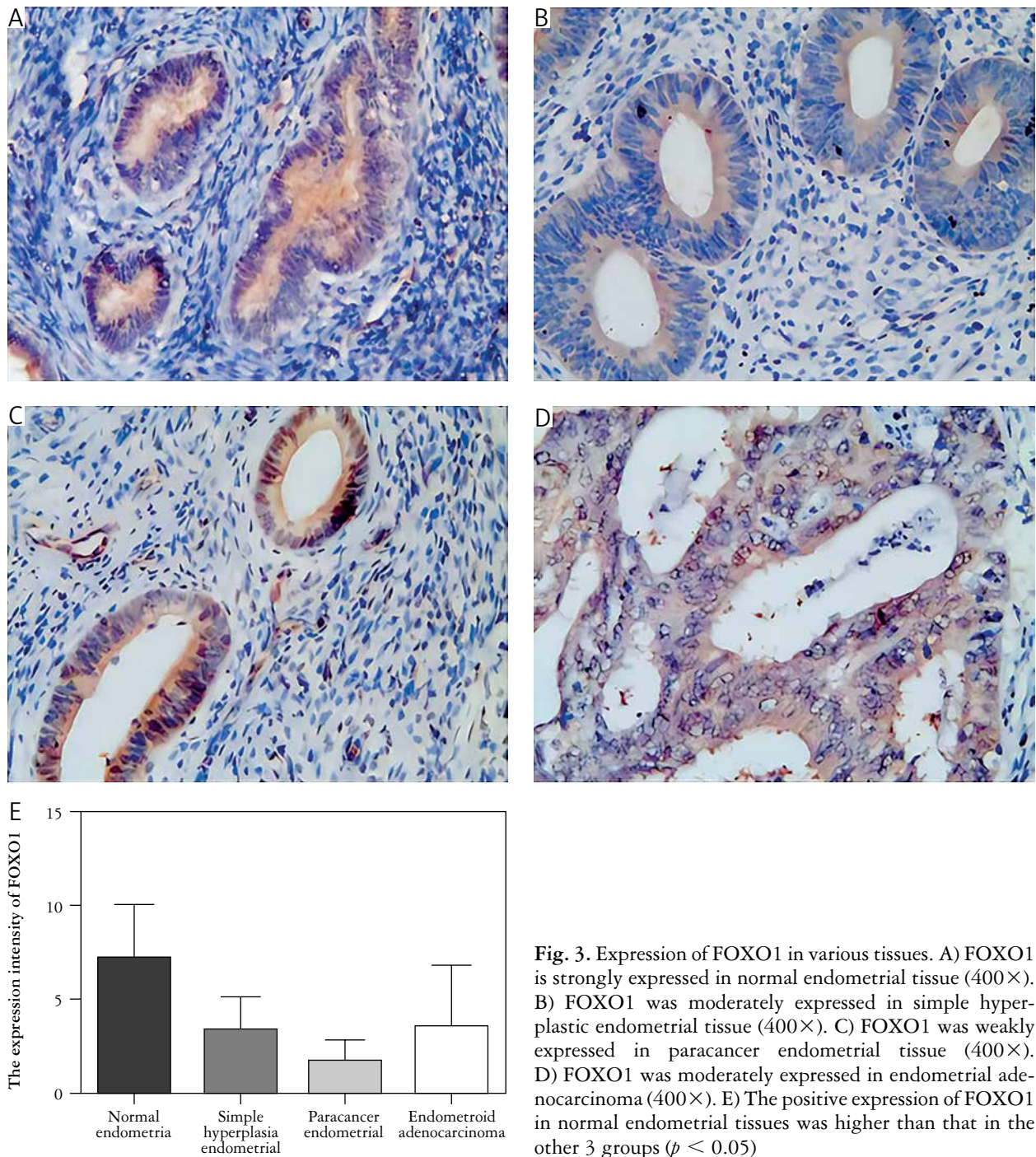
ods have been developed for monitoring endometrial lesions, including diagnostic curettage, hysteroscopic endometrial biopsy, pelvic magnetic resonance, and endometrial fluid-based cytology examination [19]. Hysteroscopic endometrial biopsy is considered to be the most accurate method for diagnosis. Surgery is still the preferred method for treatment, but chemotherapy is also an important adjuvant therapy for EC, especially for advanced EC. At present, chemotherapy resistance has become an important clinical problem that must be addressed. Although most patients with early EC have a good prognosis, the prognosis remains

poor when the disease spreads. Therefore, the discovery of novel biomarkers and therapeutic targets is important to improve patient survival.

### Expression and significance of KDM5A

#### *Biological structure and function of KDM5A*

KDM5A, also known as JARID1A or RBP2, is a histone demethylase. JARIDs are a multi-domain protein that contains the jumonji (JmjC) domain, which removes dimethyl sums on the fourth lysine of histone H3 trimethyl, including an ARID do-



**Fig. 3.** Expression of FOXO1 in various tissues. A) FOXO1 is strongly expressed in normal endometrial tissue (400 $\times$ ). B) FOXO1 was moderately expressed in simple hyperplastic endometrial tissue (400 $\times$ ). C) FOXO1 was weakly expressed in paracancer endometrial tissue (400 $\times$ ). D) FOXO1 was moderately expressed in endometrial adenocarcinoma (400 $\times$ ). E) The positive expression of FOXO1 in normal endometrial tissues was higher than that in the other 3 groups ( $p < 0.05$ )

main that binds to the CCGCCC tail of DNA [20]. A number of histone interacting PHD domains [21] and a conserved PLU-1 domain KDM5A are located on the short arm of chromosome 12 (12p13.33), with a total of 28 exons. JmjN and JmjC are specific demethylase active regions; the mutation of ARID domain affects the enzyme activities of JmjN and JmjC [22]. The PHD domain can specifically identify and bind to H3K4me2/3 [23], is structurally similar to the tail of C5HC2 LXCXE and non-T/E1A, and regulates KDM5A and pRb (retinoblastoma protein) p107 and TATA and other proteins. In summary,

KDM5A can regulate various biological activities of cells by coordinating multiple functional domains.

#### *Expression and significance of KDM5A in tumour*

Experimental data from primary tumours and animal models proved that KDM5A can promote tumourigenesis [24]. If the activity of KDM5A is weakened in various human cancer cell lines lacking pRb, then the metabolic process of cancer cells will be normal and cell division will be stopped [25]. KDM5A is highly expressed in many malignant tumours, such as

**Table 1.** There was a significant negative correlation between KDM5A and KDM5B expression in endometrioid adenocarcinoma tissues ( $r = -0.709, p < 0.001$ )

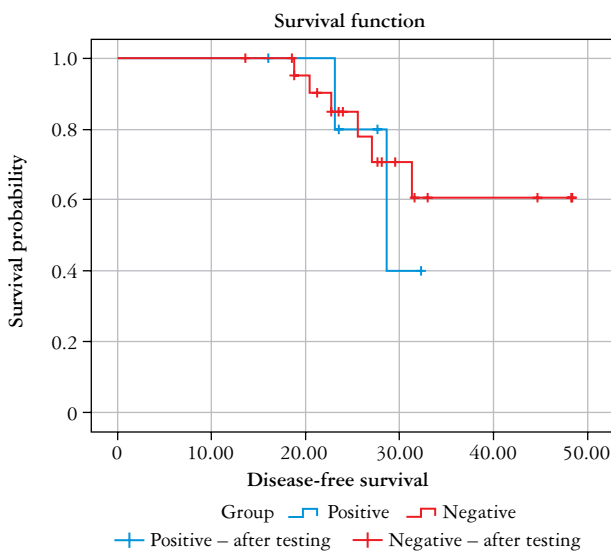
GROUP	KDM5A POSITIVE	KDM5A NEGATIVE	R-VALUE	P-VALUE
KDM5B positive	2	22	-0.709	< 0.001
KDM5A negative	5	1		

**Table 2.** There was a significant positive correlation between the expressions of KDM5A and FOXO1 in endometrioid adenocarcinoma tissues ( $r = 0.515, p = 0.004$ )

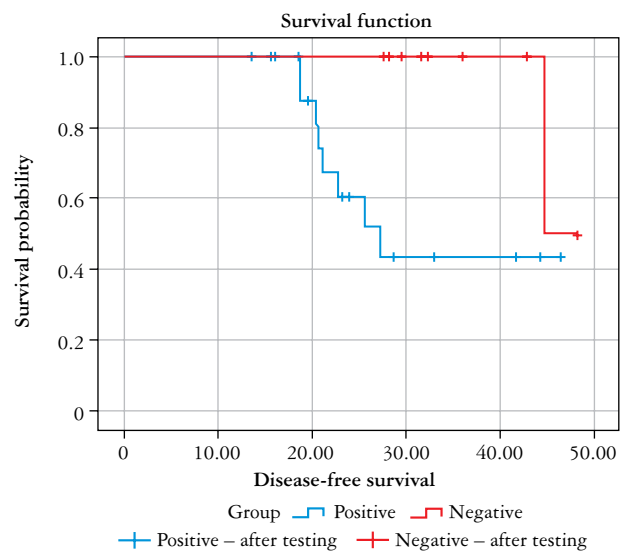
GROUP	KDM5A POSITIVE	KDM5A NEGATIVE	R-VALUE	P-VALUE
FOXO1 positive	6	6	0.515	0.004
FOXO1 negative	1	17		

**Table 3.** There was a negative correlation between the expressions of KDM5B and FOXO1 in endometrioid adenocarcinoma tissues ( $r = -0.442, p = 0.014$ )

GROUP	KDM5B POSITIVE	KDM5B NEGATIVE	R-VALUE	P-VALUE
FOXO1 positive	7	5	-0.442	0.014
FOXO1 negative	17	1		



**Fig. 4.** There was no significant difference in mean survival time between patients with positive and negative KDM5A expression of endometrial adenocarcinoma ( $p = 0.735$ )



**Fig. 5.** There was significant difference in mean survival time between patients with positive and negative KDM5B expression of endometrial adenocarcinoma ( $p = 0.001$ )

squamous cell carcinoma of the head and neck [26], prostate cancer [27], thyroid cancer, and ovarian cancer. However, KDM5A is also highly expressed in ovarian cancer cell lines SKOV3 and HO8910 and lowly expressed in 3AO cells [28]. KDM5A is mainly expressed in the nucleus and less in the cytoplasm in thyroid cancer [29]. Its expression is down-regulated in the acute phase of chronic myelogenous leukaemia; KDM5A activates programmed cell death 4 by down-regulating the expression of miR-21, stimulating leukaemia cell differentiation, and inhibiting cell proliferation [30].

At present, the application of KDM5A in tumour as an oncogene or a tumour suppressor gene has been

controversial. Dai *et al.* [31] found that, compared with that in primary glioma, the KDM5A level is lower in metastatic glioma, and KDM5A knockout increases the invasion ability of glioma cancer cells possibly because the catalytic activity of KDM5A is essential for anti-invasion function. Additionally, low levels of KDM5A are associated with poor survival in patients with glioma, and KDM5A plays an anti-invasive role by demethylating the expression of the oncogene zinc finger E-box bound to homologous heteromeric box 1. Compared with that in neighbouring normal tissues, KDM5A is highly expressed in ovarian cancer tissues and ovarian cell lines,

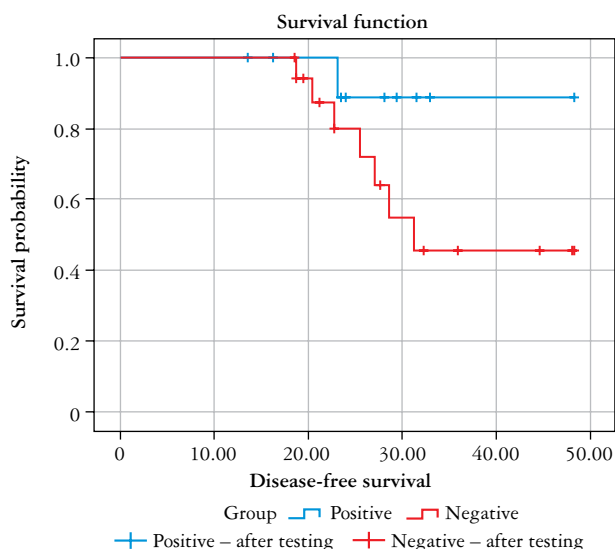


Fig. 6. There was no significant difference in mean survival time between patients with positive and negative FOXO1 expression of endometrial adenocarcinoma ( $p = 0.138$ )

especially in paclitaxel (PTX)-resistant SKOV3 cells. Chemotherapy resistance of cancer cells promotes epithelial-to-mesenchymal transformation (EMT), and one study suggested that KDM5A promotes the EMT and metastasis of ovarian cells [32]. Therefore, further research on the mechanism of KDM5A in tumour cells is needed.

DNA damage repair is one of the important mechanisms of drug resistance in tumour cells. During DNA damage, histone modifications are dynamically reshaped to adapt to the damage signal and repair of DNA in chromatin. Gong *et al.* [33] found that KDM5A, as a key regulator of the complex of domain protein ZMYND8 and NuRD (nuclear microbody structure and histone deacetylation) in DNA damage reaction, underwent H3K4me3 demethylation near the site of chromatin DNA double strand break (DSB); the lack of KDM5A could be caused by homologous recombination DSBs transcriptional silencing and repair damage. However, other studies have found that when drug-sensitive human tumour cell lines respond to various anticancer drugs, KDM5A can significantly reduce the drug sensitivity (by more than 100-fold) [34].

#### *Expression and significance of KDM5A in endometrioid adenocarcinoma*

At present, no studies have focused on the correlation of KDM5A in EC. In this study, the SP immunohistochemical method was used to detect the expression of KDM5A in 30 cases of endometrioid adenocarcinoma. According to the statistical data, the positive expression intensity of KDM5A in normal endometrial tissues was significantly higher than that in endometrioid adenocarcinoma group, paracancer en-

dometrial group, and simple hyperplastic endometrial group ( $p < 0.05$ ). Therefore, KDM5A is associated with the occurrence of endometrioid adenocarcinoma to a certain extent. The results of this experiment are contrary to the opinion of most scholars that KDM5A is highly expressed in tumours. However, individual studies found that KDM5A is lowly expressed in some tumour tissues or cancer cell lines, such as ovarian cancer 3AO cell line [28] and chronic myelogenous leukaemia in the rapid transformation stage [30]. KDM5A is speculated to play an anti-tumour role in endometrioid adenocarcinoma tissues, and its specific mechanism needs further study. Moreover, in thyroid cancer, KDM5A subcells are located in the nucleus, and only a small amount of expression is found outside the nucleus [29]. This finding is consistent with the results of the current study.

A low level of KDM5A is associated with short survival time in patients with glioma [32]. Although no correlation was found between KDM5A and prognosis of endometrioid adenocarcinoma in this study, KDM5A is not necessarily irrelevant to prognosis of endometrioid adenocarcinoma. A large number of clinical cases with longer follow-up is needed for confirmation. For the in-depth study on the relationship between KDM5A and EC, we will further expand the number of cases studied and carry out in-depth discussion based on this experiment.

#### **Expression and significance of KDM5B**

##### *Biological structure and function of KDM5B*

KDM5B, also known as plu1/JARID1B, is a histone-specific demethylase that contains 1544 amino acids. From yeast to humans, it contains highly conserved similar domain structures, including JmjN, ARID, JmjC, and Zf-C5HC2 (zinc finger structure), and 3 PH terminals: PHD1, PHD2, and PHD3 [35]. Among them, JmjN and JmjC are the basic structures of demethylation and are closely related and form the 7 residues of the ARID domain: extension of B-double helix, a-KG oxygenase superfamily, C-terminal helical domain (residues 604e671,737e753), b helical domain (residues 604e671,737e753), and a b chain (residues 673e734) that conceals the C5HC2-zinc finger structure, which is necessary for transcriptional suppression [36]. The JmjC domain catalyses the demethylation of histones by Fe (II) and hydroxylation-dependent a-KG [37]. The ARID (94e100) domain is an inactive but essential structure that contributes to substrate recognition [38]. Although the ARID domain acts as a DNA-binding domain in other members of the KDM5 family, KDM5B does not exhibit sequence specificity [39]. In e-KG oxygenase, the conserved HxD/E.H metal chelate is found near the cofactor binding site. In these domains, PHD1 can be used as an unmethylated reader of H3K4

and an antimethylated protector. Removal of PHD1 can reduce the binding of KDM5B-N to unmethylated K4 in histone 3 peptide *in vitro* [40]. As early as 1999, Johansson *et al.* [41] reported that KDM5B is specifically upregulated in breast cancer [42]. However, more than 270 residues were found to be inserted, containing the ARID PHD1 region and placing the PHD1 domain in close contact with the catalytic core. This finding may be related to substrate contact between the nucleosome and KDM5B. Thus, PHD1 is required for KDM5B to induce the demethylation of H3K4me2/3 [43]. KDM5B collaboratively inhibits cell cycle inhibitor p21 cip (CDKN1A) with activator 2C (TFAP2C) and Myc. TFAP2C-Myc-KDM5B complex promotes cell cycle progression through the direct inhibition of CDKN1A, leading to tumorigenesis, unsatisfactory therapeutic effect, and poor prognosis [44].

#### *Expression and significance of KDM5B in tumour*

Elevated levels of KDM5B have been found in a variety of human malignancies and are considered to be a transcriptional repressor associated with tumour growth, angiogenesis, invasion, metastasis, and tumour-related drug resistance [45]. Initially, KDM5B was thought to express a gene reversibly regulated by human epidermal growth factor receptor 2 (HER2). However, HER2 expression is displayed in 90% of breast cancers regardless of its level and appears to be associated with malignant progression [46]. The role of KDM5B in breast cancer, stomach cancer, liver cancer, lung cancer, and other cancers has been widely studied. MiR-137 may inhibit cell proliferation and migration by regulating KDM5B levels in breast cancer cells [47]. Breast cancer cells overexpressed with KDM5B proliferate, form breast globular cells, and exhibit enhanced clonability [48]. In oral squamous cell carcinoma, KDM5B can induce the transformation of the stem cell-like cell population in cancer between different states and inhibit cell migration and invasion [49]. Ectopic overexpression of miR-137 can inhibit the expression of KDM5B, reduce cell growth and invasion, and increase the apoptosis of bladder cancer cells [50]. In cervical squamous cell carcinoma, KDM5B is down-regulated to inhibit members of the Bcl-2 family, ultimately leading to G1 phase suppression and early apoptosis [51]. The up-regulated expression of KDM5B promoted the proliferation and migration of glioma cells and increased the tumorigenicity of glioma cells *in vivo* in glioma xenograft models [52]. Cui *et al.* [53] found and verified that KDM5B is a direct functional target of miR-194, and miR-194 regulates the proliferation, apoptosis, and invasion of oesophageal squamous cell cancer cells by targeting KDM5B. In colorectal cancer, KDM5B is involved in cell cycle regulation and promotes cell expansion and cancer stem cell maintenance.

Tarnowski *et al.* [54] found that the expression of KDM5B is positively correlated with the progression of tumour stem cells and is high in patients with distant metastasis. Additionally, KDM5B overexpression has been associated with poor prognosis and chemotherapy resistance in epithelial ovarian cancer [55].

In addition to being an oncogene, *KDM5B* has a tumour suppressive effect. The binding of KDM5B to LSD1/NuRD inhibits angiogenesis and metastasis in breast cancer cells by inhibiting chemokine C-C domain f chemokine ligand 14. Nuclear small body mass structure and the complex components of deacetylase (NuRD) are associated with KDM5B, possibly because the latter has a synergistic effect with histone deacetylase 1 and is involved in tumour inhibition [56]. These findings highlighted the anti-tumour effect of KDM5B in triple-negative breast cancer cells and identify a novel mechanism that can mediate the transcriptional regulation of KDM5B. However, the molecular mechanism by which KDM5B promotes gene regulation and plays the opposite role in carcinogenesis remains unclear.

#### *Expression and significance of KDM5B in endometrioid adenocarcinoma*

The immunohistochemical surfactant protein (SP) method was used to detect the expression of KDM5B in 30 cases of endometrioid adenocarcinoma. The results showed that the positive expression intensity of KDM5B in endometrioid adenocarcinoma was significantly higher than that in the paracancer endometrium group, pure hyperplasia endometrium group, and normal endometrium group ( $p < 0.05$ ), suggesting that KDM5B may be involved in the occurrence and development of endometrioid adenocarcinoma. This finding is consistent with the opinion of most scholars that KDM5B is highly expressed in tumours and is related to the occurrence of tumours. Although KDM5B is expressed in normal endometrium, pure hyperplastic endometrium, and paracarcinoma endometrium to a certain extent, whether it is affected by oestrogen and other biological factors remains unclear. Li *et al.* [57] recently proposed that the expression of KDM5B is significantly increased in EC tissues and cell lines, and its increased expression is related to the high pathologic grade of EC and PTX resistance. They also found that the silencing of KDM5B through the miR-29c-3p/KDM5B signalling pathway can lead to the reversal of PTX resistance, providing new insights into the mechanisms of PTX resistance in EC cells.

TFAP2C-Myc-KDM5B complex in breast cancer tissue promotes cell cycle progression by directly inhibiting cell cycle inhibitor CDKN1A, thus leading to poor tumour prognosis [58]. In this study, Kaplan-Meier survival analysis showed that the over-

all survival rate of the KDM5B positive expression group was significantly lower than that of the negative expression group ( $p < 0.05$ ), suggesting that KDM5B may be associated with the poor prognosis of endometrioid adenocarcinoma.

Many compounds targeting KDM5B have been developed. Fe(II) and a-KG are 2 indispensable factors in the demethylation of KDM5B, and pharmaceutical chemists make full use of a-KG or compounds chelated with Fe (II) in the development of KDM5B drugs. However, all KDM5B inhibitors are currently being evaluated at an early stage, and no compounds have entered clinical trials. Nevertheless, KDM5B has achieved amazing research results as an anticancer drug target; with further research, KDM5B inhibitors will soon be available for clinical use [59].

## Expression and significance of FOXO1

### *Biological structure and function of FOXO1*

FOXO1, also known as FOXO1a, is a member of the FOXO family [60]. As a multifunctional transcription factor, FoxO1 regulates the transcription of target genes and is involved in human growth and development, metabolism, autophagy, DNA damage or repair, cell apoptosis, oxidative stress resistance [61], angiogenesis, and other life processes. It is also closely related to the occurrence and development of tumours. Each FOX family contains a conserved Fox domain, which is bound to DNA, 3  $\alpha$  helices (helix 1, 2, and 3), and 2 winged ring-type structures. The *FOXO1* gene is located on human chromosome 13q14.1, encoding 655 amino acids [62]. The N-terminus contains DNA binding domain FK1, and the C-terminus contains a transcription activation domain, nuclear localisation signal peptide, and nuclear output sequence rich in proline and fil/threonine [63]. FOXO1 also has AKT/PKB phosphorylation sites corresponding to Thr24 Ser256 and Ser319 and provides the same DNA-binding sequence TTGTTTAC to different target genes for transcriptional regulation [64].

The *FOXO1* gene plays an indispensable role in cell oxidation. When cells are damaged and cannot be repaired, FOXO1 activates oxidative stress and induces cell apoptosis [65]. The transcriptional activity of FOXO1 is regulated by multiple levels, such as gene expression, post-translational modification, and protein interactions. When FOXO1 is phosphorylated/acetylated, the nuclear FOXO1 shifts and the transcriptional activity decreases, thus promoting tumorigenesis [66]. FOXO1 is down-regulated in the insulin/phosphoinositol-3/kinase signalling pathway, which enhances cell proliferation and ultimately leads to cancer [67]. Therefore, most scholars believe that FOXO1 is a tumour suppressor [68].

## Expression and significance of FOXO1 in tumour

As a tumour suppressor, FOXO1 inhibits the growth of prostate cancer, breast cancer, glioblastoma, colon cancer, and other tumours by regulating pro-apoptotic genes [69]. In prostate cancer, FOXO1 is phosphorylated by PTEN-FOXO1 regulation [70], resulting in its down-regulation and uninhibited androgen receptor signalling pathway, ultimately leading to the proliferation of cancer cells [71]. Additionally, FOXO1 transcription and its ability to bind to DNA is inhibited by protein-protein interaction, ultimately resulting in cell apoptosis. The function of death and cell cycle arrest is decreased [72]. Silva *et al.* [73] found that in breast cancer cells, after FOXO1 is phosphorylated, its transcriptional activity decreases and cancer cells proliferate; opposite results are observed when FOXO1 activity increases, indicating that FOXO1 is closely related to the occurrence and development of breast cancer. In drug-resistant breast cancer cells, FOXO1 undergoes deacetylation and increased transcriptional activity, resulting in its up-regulation that increases the expression of multi-drug resistant protein MRP2 and consequently leads to the drug resistance of cancer cells [74]. In liver cancer cells, the transcriptional activity of FOXO1 increases, and the cancer cell cycle stagnates in the G phase, thus reducing the proliferation of cancer cells [75]. Inhibiting the activity of FOXO1 can promote the proliferation and metastasis of cancer cells [76]. FOXO1 has also been closely associated with the occurrence and development of oesophageal cancer [77], rhabdomyosarcoma [78], lymphoma [79], and other cancers. FOXO1 can regulate glucose metabolism and fat metabolism, providing a new idea to further understand the mechanism of tumour occurrence, development, and treatment.

### *Expression and significance of FOXO1 in endometrioid adenocarcinoma*

FOXO1 is one of the downstream target genes of AKT, a Serine/threonine kinase regulated by the PTEN-PI3K signalling pathway, and its overexpression of phosphorylation leads to oncogenesis. When phosphorylated, nuclear FOXO1 shifts, resulting in transcriptional activity loss. Subsequently, Skp2 phosphorylates FOXO1 at Ser256, resulting in the ubiquitination of FOXO1, which is degraded by proteases and loses its function of inhibiting cell proliferation [80]. FOXO1 is downregulated in endometrioid adenocarcinoma cell lines with Skp2 overexpression [81]. Hoekstra *et al.* [82] showed that the AKT inhibitor in EC suppresses the AKT signalling pathway, increases the FOXO1 level in the nucleus, and promotes cell apoptosis. In EC, FOXO1 is essential for inhibiting cell proliferation and DNA damage inducer gene (*GADD45 $\alpha$* ) expression, suggesting that

the loss of FOXO1 disrupts endometrial homeostasis, promotes cell proliferation, and increases susceptibility to genotoxic damage [83].

In this study, the SP immunohistochemical method was used to detect FOXO1 expression in 30 cases of endometrioid adenocarcinoma. The results showed that the positive expression intensity of FOXO1 in normal endometrial tissues was significantly higher than that in the endometrioid adenocarcinoma group, paracancer endometrium group, and pure hyperplasia endometrium group ( $p < 0.05$ ). Combined with previous studies, this finding indicated that FOXO1 is closely related to the pathogenesis of endometrioid adenocarcinoma, which is also consistent with the view of most scholars that FOXO1 is lowly expressed in tumours and related to the pathogenesis of tumours [84]. Abhijit *et al.* [85] reported that the shift of FOXO1 from the nucleus to the cytoplasm implies the loss of its pro-apoptotic function. Mohsen *et al.* [86] found that the FOXO1 protein level in EC patients was significantly lower than that in the control group. No statistical significance in phosphorylated FOXO1 occurred between EC patients and the control group, but the P-FoxO1/FOXO1 ratio in EC patients was increased ( $p < 0.01$ ), suggesting the importance of FOXO1 activity in the biology of EC cells. Additionally, enhancing the function of FOXO1 may be a powerful strategy against the progression of EC. In the current study, FOXO1 was mainly located in the cytoplasm in endometrioid adenocarcinoma tissues and in the nucleus in the other 3 groups. This result again confirmed that FOXO1 translocation from the nucleus to the cytoplasm reduces its transcriptional activity, inhibits cell apoptosis, and eventually leads to tumourigenesis. In summary, FOXO1 plays an important role in the occurrence and development of endometrioid adenocarcinoma. Further study of FOXO1 and its mechanism is expected to provide a new target for the treatment of endometrioid adenocarcinoma.

Kaplan-Meier survival analysis showed that the survival rate of patients with positive FOXO1 expression was higher than that of patients with negative FOXO1 expression, but the difference was not statistically significant ( $p = 0.138$ ). This finding indicated that FoxO1 may not be significantly associated with the prognosis of patients with endometrioid adenocarcinoma. Further studies are needed for confirmation.

#### Relationship between KDM5B and FOXO1 expression in endometrioid adenocarcinoma

Increased levels of intracellular oxidative stress have been associated with a variety of human malignancies. As a new key regulator of cellular REDOX state, transcription cofactor KDM5, interacts with lysine deacetylase HDAC4 to promote Foxo deacetyl-

ation, and it activates oxidative stress resistance genes through interaction with Foxo. Promoting KDM5 to recruit KDM5-FOXO co-regulated genes enhances the binding ability of transcription factor FOXO to DNA, thus enhancing the transcriptional activity of Foxo [87].

In this study, the expression of KDM5A, KDM5B, and FOXO1 in endometrioid adenocarcinoma was detected, and Spearman statistical analysis was used to analyse the expression differences. The results showed that the expression of KDM5A in endometrioid adenocarcinoma was positively correlated with the expression of FOXO1 ( $r = 0.515, p = 0.004$ ). In endometrioid adenocarcinoma, KDM5A and FOXO1 are closely related to endometrial carcinogenesis. The positive expression of KDM5B was negatively correlated with FOXO1, KDM5A, and KDM5B in endometrioid adenocarcinoma ( $r = -0.442, p = 0.014, r = -0.709, p < 0.001$ ). Although KDM5A and KDM5B are members of the KDM5 family of transcription cofactors, KDM5A may play a role in deacetylating FOXO1 and activating oxidative stress resistance genes in endometrioid adenocarcinoma, thus enhancing the binding ability of transcription factor FOXO1 to DNA and increasing its transcriptional activity. As a result, tumourigenesis is inhibited. However, KDM5B may play the role of protein demethylation and show strong transcriptional inhibition, thus affecting cell differentiation, stem cell self-renewal, and other developmental processes. The possible molecular biological basis of KDM5A, KDM5B, and FOXO1 has not yet been clarified. Further research is necessary to clarify the role of these 3 in the occurrence and development, treatment, and prognosis of endometrioid adenocarcinoma.

#### Conclusions

Our results showed that KDM5A and FOXO1 are lowly expressed in endometrioid adenocarcinoma, and KDM5B is highly expressed in endometrioid adenocarcinoma. These 3 may be involved in the pathology of endometrioid adenocarcinoma. KDM5B is associated with poor prognosis of endometrioid adenocarcinoma. The expression levels of KDM5A and FOXO1 are positively correlated, and the expression levels of FOXO1 and KDM5B are negatively correlated.

#### Disclosures

1. This study is in accordance with the Declaration of Helsinki, and it has been reviewed by the Ethics Committee of the Jiangxi Cancer Hospital; the ethical review approval code is 2022ky294. All participants must provide written and verbal informed consent to participate in the study.

2. The labelled dataset used to support the findings of this study are available from the corresponding author upon request.
3. The work was funded by the National Natural Science Foundation of China (grant no. 82060477), Jiangxi Provincial Natural Science Foundation (grant no. 2020BAB206054), Science and Technology Project of Health Commission of Jiangxi (grant no. 202120073), Nanchang Science and Technology Support Plan Key Project (grant no. Hongkezi2019-258-3), Nanchang Key Laboratory for Precision Therapy of Gynaecological Tumours (grant no. 2020NCZDSY-003), 2021 Nanchang High-level Science and Technology Innovation Talents "Double Hundred Plan" Project (grant no. Hongkezi 2021-156-29), and Nanchang Advantage Science and Technology Innovation Team Project (grant no. 2019-15-3).
4. Conflicts of interest: None.

## References

1. Koh WJ, Abu-Rustum NR, Bean S, et al. Uterine Neoplasms, Version 1.2018, NCCN Clinical Practice Guidelines in Oncology. *J Natl Compr Canc Netw* 2018;16: 170-199.
2. Moir-Meyer GL, Pearson JF, Lose F, et al. Rare germline copy number deletions of likely functional importance are implicated in endometrial cancer predisposition. *Hum Genet* 2015; 134: 269-278.
3. Yu XY, Ma LG. Progress in clinical diagnosis and treatment of endometrial carcinoma. *J Clin Med Res Pract* 2017; 2: 190-193.
4. Hu D, Jablonowski C, Cheng PH, et al. KDM5A regulates a translational program that controls p53 protein expression. *iScience* 2018; 9: 84-100.
5. Guo X, Guan MM, Liu CH, et al. Application of hysteroscopy in diagnosis and treatment of endometrial cancer. *Chin J Pract Gynecol Obst* 2017; 33: 13-15.
6. Xiaojun C, Xuezhen L. Selection and implementation of fertility preservation in early endometrial cancer. *Chinese Pract Gynecol Obst J* 2019; 35: 14-19.
7. China research hospital association of obstetrics and gynecology professional committee. *Clin Res Pract* 2019; 20: 369-373.
8. Lin Z Q. Paying attention to the standardized and individualized treatment of endometrial cancer. *Chin J Practical Gynecol Obst* 2017; (05): 5-7.
9. Zhang LW, Ma J, Jin Y, Hu QB, Li Y, Wang Y. Expression of KDM5B gene in ovarian cancer and its effect on drug resistance in ovarian cancer. *Adv Modern Obst Gynecol* 2017; 26: 161-164.
10. Hou J, Wu J, Dombkowski A, et al. Genomic amplification and a role in drug-resistance for the KDM5A histone demethylase in breast cancer. *Am J Transl Res* 2012; 4: 247-256.
11. Hinohara K, Wu HJ, Vigneau S, et al. KDM5 histone demethylase activity links cellular transcriptomic heterogeneity to therapeutic resistance. *Cancer Cell* 2019; 35: 330-332.
12. Liu X, Greer C, Secombe J. KDM5 interacts with Foxo to modulate cellular levels of oxidative stress. *PLoS Genet* 2014; 10: e1004676.
13. Qing-Lei G, Fei Y, Jing L, et al. PTEN coding product: a marker for tumorigenesis and progression of endometrial carcinoma. *Ai Zheng* 2003; 22: 640-644.
14. Siegel RL, Miller KD, Goding Sauer A, et al. Colorectal cancer statistics. *CA Cancer J Clin* 2020; 2020: 10.3322/caac.21601.
15. Nagle CM, Olsen CM, Ibiebele TI, et al. Glycemic index, glycemic load and endometrial cancer risk: results from the Australian National Endometrial Cancer study and an updated systematic review and meta-analysis. *Eur J Nutr* 2013; 52: 705-715.
16. Zhang P, Gao K, Jin X, et al. Endometrial cancer-associated mutants of SPOP are defective in regulating estrogen receptor  $\alpha$  protein turnover. *Cell Death Dis* 2015; 6: e1687.
17. Siegel RL, Miller KD, Jemal A. Cancer statistics 2016. *CA Cancer J Clin* 2016; 66: 7-30.
18. Kuramoto H. Cytological characteristics of endometrial phasing using the specimens prepared with the liquid-based procedure: comparison with the conventional procedure. *Acta Cytol* 2016; 60: 429-437.
19. Chen XL, Jin P, Zhao J, et al. Application of modified endometrial sampler in the early diagnosis of endometrial lesion biopsy. *Chin J Exp Diag* 2015; 19: 1096-1098.
20. LI L, WANG L, SONG P, et al. Critical role of histone demethylase RBP2 in human gastric cancer angiogenesis. *Mol Cancer* 2014; 13: 81.
21. Coffey PJ, Burgering BMT. Forkhead-box transcription factors and their role in the immune system. *Nat Rev Immunol* 2004; 4: 889-899.
22. Horton JR, Engstrom A, Zoeller EL, et al. Characterization of a linked Jumonji domain of the KDM5/JARID1 family of histone H3 lysine 4 demethylases. *J Biol Chem* 2016; 291: 2631-2646.
23. Beshiri ML, Islam A, Dewaal DC, et al. Genome-wide analysis using ChIP to identify isoform-specific gene targets. *J Vis Exp* 2010; (41): e2101.
24. Yang GJ, Zhu MH, Lu XJ, et al. The emerging role of KDM5A in human cancer. *J Hematol Oncol* 2021; 14: 30.
25. Váraljai R, Islam AB, Beshiri ML, et al. Increased mitochondrial function downstream from KDM5A histone demethylase rescues differentiation in pRB-deficient cells. *Genes Dev* 2015; 29: 1817-1834.
26. Dubot C, Bernard V, Sablin MP, et al. Comprehensive genomic profiling of head and neck squamous cell carcinoma reveals FGFR1 amplifications and tumour genomic alterations burden as prognostic biomarkers of survival. *Eur J Cancer* 2018; 91: 47-55.
27. Vieira FQ, Costa-Pinheiro P, Ramalho-Carvalho J, et al. Deregulated expression of selected histone methylases and demethylases in prostate carcinoma. *Endocr Relat Cancer* 2013; 21: 51-61.
28. Jia C, WANG J, Shao GB, et al. Expression of LSD1 and KDM5 family in ovarian cancer cells and the effect of LSD1 on cell proliferation and migration. *J Southeast Univ* 2016; 35: 350-354.
29. Kong LL, Man DM, Wang T, et al. siRNA targeting RBP2 inhibits expression, proliferation, tumorigenicity and invasion in thyroid carcinoma cells. *Oncol Lett* 2015; 10: 3393-3398.
30. Zhou M, Zeng J, Wang X, et al. Histone demethylase RBP2 decreases miR-21 in blast crisis of chronic myeloid leukemia. *Oncotarget* 2015; 6: 1249-1261.
31. Dai B, Huang H, Guan F, et al. Histone demethylase KDM5A inhibits glioma cells migration and invasion by down regulating ZEB1. *Biomed Pharmacother* 2018; 99: 72-80.
32. Feng T, Wang Y, Lang Y, et al. KDM5A promotes proliferation and EMT in ovarian cancer and closely correlates with PTX resistance. *Mol Med Rep* 2017; 16: 3573-3580.
33. Gong F, Clouaire T, Aguirrebengoa M, et al. Histone demethylase KDM5A regulates the ZMYND8-NuRD chromatin remodeler to promote DNA repair. *J Cell Biol* 2017; 216: 1959-1974.
34. Sharma SV, Lee DY, Li B, et al. A chromatin-mediated reversible drug-tolerant state in cancer cell subpopulations. *Cell* 2010; 141: 69-80.
35. Pilka ES, James T, Lisztwan JH. Structural definitions of Jumonji family demethylase selectivity. *Drug Discovery Today* 2015; 20: 743-749.

36. Yang X, Ziqi Z, Gang H, et al. JARID1B is a histone H3 lysine 4 demethylase up-regulated in prostate cancer. *Proc Natl Acad Sci U S A* 2007; 104: 9226-19231.
37. Johansson C, Velupillai S, Tumber A, et al. Structural analysis of human KDM5B guides histone demethylase inhibitor development. *Nat Chem Biol* 2016; 12: 539-545.
38. Horton JR, Engstrom A, Zoeller EL, et al. Characterization of a linked Jumonji domain of the KDM5/JARID1 family of histone H3 lysine 4 demethylases. *J Biol Chem* 2016; 291: 2631-2646.
39. Patsialou A, Wilsker D, Moran E. DNA-binding properties of ARID family proteins. *Nucleic Acids Res* 2005; 33: 66-80.
40. Sanchez R, Zhou MM. The PHD finger: a versatile epigenome reader. *Trends Biochem Sci* 2011; 36: 364-372.
41. Johansson C, Velupillai S, Tumber A, et al. Structural analysis of human KDM5B guides histone demethylase inhibitor development. *Nat Chem Biol* 2016; 12: 539-545.
42. Lu PJ, Sundquist K, Baeckstrom D, et al. A novel gene (PLU-1) containing highly conserved putative DNA/chromatin binding motifs is specifically up-regulated in breast cancer. *J Biol Chem* 1999; 274: 15633-15645.
43. Zhang Y, Yang H, Guo X, et al. The PHD1 finger of KDM5B recognizes unmodified H3K4 during the demethylation of histone H3K4me2/3 by KDM5B. *Protein Cell* 2014; 5: 837-850.
44. Viré E, Curtis C, Davalos V, et al. The breast cancer oncogene EMSY represses transcription of antimetastatic microRNA miR-31. *Molecular Cell* 2014; 53: 806-818.
45. Rotili D, Mai A. Targeting histone demethylases a new avenue for the fight against cancer. *Genes Cancer* 2011; 2: 663-679.
46. Barrett A, Madsen B, Copier J, et al. PLU-1 nuclear protein, which is upregulated in breast cancer, shows restricted expression in normal human adult tissues: a new cancer/testis antigen? *Int J Cancer* 2002; 101: 581-588.
47. Denis H, Van Grembergen O, Delatte B, et al. MicroRNAs regulate KDM5 histone demethylases in breast cancer cells. *Mol Biosyst* 2016; 12: 404-413.
48. Bamodu OA, Huang WC, Lee WH, et al. Aberrant KDM5B expression promotes aggressive breast cancer through MALAT1 overexpression and downregulation of hsa-miR-448. *BMC Cancer* 2016; 16: 160.
49. Facompri ND, Harmeyer KM, Sole X, et al. JARID1B enables transit between distinct states of the stem-like cell population in oral cancers [published correction appears in *Cancer Res* 2017; 77: 7136]. *Cancer Res* 2016; 76: 5538-5549.
50. Veerakumarasivam A, Kodiappan R, Chan SC, Razack AH. Abstract 5213: microRNA-mediated loss of KDM5B expression leads to suppression of the malignant bladder cancer phenotype. *J Nucl Med* 2014; 74: 5213-5213.
51. Cui Z, Song L, Hou Z, et al. PLU-1/JARID1B overexpression predicts proliferation properties in head and neck squamous cell carcinoma. *Oncol Rep* 2015; 33: 2454-2460.
52. Fang L, Zhao J, Wang D, Zhu L, Wang J, Jiang K. Jumonji AT-rich interactive domain 1B overexpression is associated with the development and progression of glioma [published correction appears in *Int J Mol Med* 2016; 38: 976]. *Int J Mol Med* 2016; 38: 172-182.
53. Cui G, Liu D, Li W, et al. Original research: miR-194 inhibits proliferation and invasion and promotes apoptosis by targeting KDM5B in esophageal squamous cell carcinoma cells. *Exp Biol Med (Maywood)* 2017; 242: 45-52.
54. Tarnowski M, Czerewaty M, Deskur A, et al. Expression of cancer testis antigens in colorectal new prognostic and therapeutic implications. *Dis Markers* 2016; 2016: 1-9.
55. Wang L, Mao Y, Du G, He C, Han S. Overexpression of JARID1B is associated with poor prognosis and chemotherapy resistance in epithelial ovarian cancer. *Tumour Biol* 2015; 36: 2465-2472.
56. Li Q, Shi L, Gui B, et al. Binding of the JmjC demethylase JARID1B to LSD1/NuRD suppresses angiogenesis and metastasis in breast cancer cells by repressing chemokine CCL14. *Cancer Res* 2011; 71: 6899-6908.
57. Li L, Shou H, Wang Q, Liu S. Investigation of the potential theranostic role of KDM5B/miR-29c signaling axis in paclitaxel resistant endometrial carcinoma. *Gene* 2019; 694: 76-82.
58. Wong PP, Miranda F, Chan KV, et al. Histone demethylase KDM5B collaborates with TFAP2C and MYC to repress the cell cycle inhibitor p21cip (CDKN1A). *Mol Cell Biol* 2012; 32: 1633-1644.
59. Maiese K, Chong ZZ, Shang YC, et al. Clever cancer strategies with FoxO transcription factors. *Cell Cycle* 2008; 7: 3829-3839.
60. Salih DA, Brunet A. FoxO transcription factors in the maintenance of cellular homeostasis during aging. *Curr Opin Cell Biol* 2008; 20: 126-136.
61. Kaestner KH, Knochel W, Martinez DE. Unified nomenclature for the winged helix/forkhead transcription factors. *Genes Dev* 2000; 14: 142-146.
62. Obsi T, Obsilova V. Structure/function relationships underlying regulation of FOXO transcription factors. *Oncogene* 2008; 27: 2263-2275.
63. Espenshade PJ. SREBPs: sterol-regulated transcription factors. *J Cell Sci* 2006; 119: 973-976.
64. Sedding DG. FoxO transcription factors in oxidative stress response and ageing – a new fork on the way to longevity? *Biol Chem* 2008; 389: 279-283.
65. Vogt PK, Jiang H, Aoki M. Triple layer control: phosphorylation, acetylation and ubiquitination of FOXO proteins. *Cell Cycle* 2005; 4: 908-913.
66. Biggs WH, Meisenhelder J, Hunter T, Cavenee WK, Arden KC. Protein kinase B/Akt-mediated phosphorylation promotes nuclear exclusion of the winged helix transcription factor FKHR1. *Proc Natl Acad Sci U S A* 1999; 96: 7421-7426.
67. Katoh M, Igarashi M, Fukuda H, Nakagama H, Katoh M. Cancer genetics and genomics of human FOX family genes. *Cancer Lett* 2013; 328: 198-206.
68. Greer EL, Brunet A. FOXO transcription factors in ageing and cancer. *Acta Physiol (Oxf)* 2008; 192: 19-28.
69. Ma Q, Fu W, Li P, et al. FOXO1 mediates PTEN suppression of androgen receptor N- and C-terminal interactions and co-activator recruitment. *Mol Endocrinol* 2009; 23: 213-225.
70. Dong XY, Chen C, Sun X, et al. FOXO1A is a candidate for the 13q14 tumor suppressor gene inhibiting an androgen receptor signaling in prostate cancer. *Cancer Res* 2006; 66: 6998-7006.
71. Li P, Lee H, Guo S, et al. AKT – independent protection of prostate cancer cells from apoptosis mediated through complex formation between the androgen receptor and FKHR. *Mol Cell Biol* 2003; 23: 104-118.
72. Silva J, Cavazos DA, Donzis E, et al. Akt induced tamoxifen resistance is associated with altered FKHR regulation. *Cancer Invest* 2007; 25: 569-573.
73. Guttilla IK, White BA. Coordinate regulation of FOXO1 by miR-27a, miR-96 and miR-182 breast cancer cells. *J Biol Chem* 2009; 284: 23204-23216.
74. Choi HK, Cho KB, Phuong NT, et al. SIRT1-mediated FOXO1 deacetylation is essential for multidrug resistance-associated protein 2 expression in tamoxifen-resistant breast cancer cells. *Mol Pharm* 2013; 107: 2517-2527.
75. Lee SY, Lee GR, Woo DH, et al. Depletion of aurora a leads to upregulation of FOXO1 to induce cell cycle arrest in hepatocellular carcinoma cells. *Cell Cycle* 2013; 12: 67-75.
76. Xu D, He X, Chang Y, et al. Inhibition of miR-96 expression reduces cell proliferation and clonogenicity of HepG2 hepatoma cells. *Oncol Rep* 2013; 29: 653-661.
77. Beales IL, Ogunwobi O, Cameron E, et al. Activation of Akt is increased in the dysplasia-carcinoma sequence in Barrett's oesophagus and contributes to increased proliferation and in-

- hibition of apoptosis :a histopathological and functional study. *BMC Cancer* 2007; 7: 97.
78. Jothi M, Mal M, Keller C, et al. Small molecule inhibition of PAX3-FOXO1 through AKT activation suppresses malignant phenotypes of alveolar rhabdomyosarcoma. *Mol Cancer Ther* 2013; 12: 2663-2674.
  79. Xie L, Ushmorov A, Leithauser F, et al. FOXO1 is a tumor suppressor in classical Hodgkin lymphoma. *Blood* 2012; 119: 3503-3511.
  80. Huang H, Regan KM, Wang F, et al. Skp2 inhibits FOXO1 in tumor suppression through ubiquitin-mediated degradation. *Proc Natl Acad Sci* 2005; 102: 1649-1654.
  81. Lahav-Baratz S, Ben-Izhak O, Sabo E, et al. Decreased level of the cell cycle regulator p27 and increased level of its ubiquitin ligase Skp2 in endometrial carcinoma but not in normal secretory or in hyperstimulated endometrium. *Mol Hum Rep* 2004; 10: 567-572.
  82. Myatt SS, Wang J, Monteiro LJ, et al. Definition of microRNAs that repress expression of the tumor suppressor gene FOXO1 in endometrial cancer. *Cancer Res* 2010; 70: 367-377.
  83. Goto T, Takano M, Albergaria A, et al. Mechanism and functional consequences of loss of FOXO1 expression in endometrioid endometrial cancer cells. *Oncogene* 2008; 27: 9-19.
  84. Hoekstra AV, Ward EC, Hardt JL, et al. Chemosensitization of endometrial cancer cells through AKT inhibition involves FOXO1. *Gynecol Oncol* 2008; 108: 609-618.
  85. Mazumdar A, Kumar R. Estrogen regulation of Pak1 and FKHR pathways in breast cancer cells. *FEBS Lett* 2003; 535: 6-10.
  86. Korani M, Fallah S. Evaluating the p-FOXO1/FOXO1 ratio: an alternative strategy for endometrial cancer diagnosis. *Int J Clin Med* 2015; 6: 217-226.
  87. Liu X, Greer C, Secombe J. KDM5 interacts with FOXO to modulate cellular levels of oxidative stress. *PLoS Gen* 2014; 10: e1004676.

### Address for correspondence

Jun Gao, MD  
Jiangxi Cancer Hospital  
Jiangxi, China  
e-mail: drgaojun@yeah.net