

CASE REPORT

ATYPICAL LYMPH NODE INVOLVEMENT IN A RARE CASE OF KIKUCHI-FUJIMOTO DISEASE: A CASE REPORT AND LITERATURE REVIEWJAKUB STANEK¹, JAGODA JAKUBIK-STANEK², DOMINIK PAPROCKI³, PIOTR KRÓL⁴, JAROSŁAW JAKUBIK¹¹2nd Department of Surgical Oncology, Copernicus Memorial Multi-Specialist Oncology and Trauma Center, Lodz, Poland²Department of Biomedical Chemistry, Faculty of Health Sciences, Medical University of Lodz, Lodz, Poland³Department of Pathology, Chair of Oncology, Medical University of Lodz, Lodz, Poland⁴Emergency Department, Copernicus Memorial Multi-Specialist Oncology and Trauma Center, Lodz, Poland

Kikuchi-Fujimoto disease (KFD) is a rare, benign condition that often mimics infectious or malignant disorders. We report the case of a 36-year-old woman with atypical lymphadenopathy involving axillary, supraclavicular, and infraclavicular lymph nodes, without cervical involvement. Initial treatment with antibiotics and acetaminophen was ineffective. Laboratory tests excluded infection and other underlying diseases, while ultrasonography confirmed lymphadenopathy. Excisional biopsy revealed histopathological findings consistent with KFD. Surgical removal of the affected lymph nodes resulted in complete symptom resolution. This case highlights the importance of considering KFD in unexplained lymphadenopathy and the diagnostic value of excisional biopsy.

Key words: Kikuchi-Fujimoto disease, histiocytic necrotizing lymphadenitis, excisional biopsy, case report.

Introduction

Kikuchi-Fujimoto disease (KFD) is also known as histiocytic necrotizing lymphadenitis. It is a rare and benign condition that most commonly presents with enlargement of the cervical lymph nodes, fever, and night sweats. The disease was first described in Japan in 1972 by Dr. Masahiro Kikuchi and Y. Fujimoto [1, 2]. Although it occurs most frequently in individuals of Asian descent, cases have been reported worldwide [3–5]. It predominantly affects young adults, particularly women under 40 [6–8]. The aetiology and pathogenesis of KFD remain unknown. Viral infections and autoimmune mechanisms are suspected to be contributing factors [9, 10]. Histopathological examination of the affected lymph nodes remains the gold standard for diagnosis. Although generally benign and self-

limiting, awareness of KFD is essential to avoid misdiagnosis and unnecessary aggressive treatment.

This report presents a rare case of KFD in a 36-year-old woman with isolated left-sided axillary, supraclavicular, and infraclavicular lymphadenopathy, initially suspected of having an infectious or malignant aetiology. The diagnostic process, clinical course, histopathological findings, and resolution following surgical excision are discussed in the context of current literature.

Case report

A 36-year-old woman was admitted to our hospital with a persistent cough, fever, and axillary lymphadenopathy lasting for two months. Her first fever occurred after pharyngitis.

Her body temperature rose as her blood pressure increased. She was initially treated with a two-week course of oral antibiotics and acetaminophen to reduce the temperature. Physical examination revealed swollen axillary, supraclavicular, and infraclavicular lymph nodes on the left side. The lymph nodes were non-tender, mobile, and firm. Ultrasonographic evaluation confirmed lymphadenopathy, with the largest lymph node in the axillary region measuring 37 × 15 mm. Chest X-ray and abdominal ultrasound (US) did not show any abnormalities. Blood examination laboratory tests revealed leukopenia. Peripheral blood smear analysis demonstrated lymphocytopenia, granulocytopenia, and eosinopenia. Elevated inflammatory markers, including C-reactive protein (CRP), were detected. Serum lactate dehydrogenase (LDH) levels were elevated. Coagulation tests showed a slightly prolonged activated partial thromboplastin time and prothrombin time. An increased level of β-2-microglobulin was detected in the patient's serum. Epstein-Barr virus (EBV), parvovirus (B19), cytomegalovirus (CMV), and serological assays were also conducted. Epstein-Barr virus, B19 and CMV capsid IgG tested positive, while capsid IgM tested negative. These results suggest that the patient likely had a history of exposure to EBV, B19, and CMV without evidence of active or recent infection (Table I).

Kikuchi-Fujimoto disease is an inflammatory process involving mainly cervical lymph nodes. Here we present the case with distinctive histopathologic features, however lymphadenopathy occurred in a group of axillary, supraclavicular, and infraclavicular lymph

nodes on the left side. Other less often affected sites include mediastinal, abdominal and inguinal groups. First sample was collected by core needle biopsy which showed complete effacement of lymph node's histoarchitecture and replacement by multiple histiocytes with pale cytoplasm, polymorphic lymphocytes (mainly of T-lineage) and scattered plasmacytes. Suggestion of KFD was made in the pathologic result followed by excision of a cluster of lymph nodes measuring 9 × 4.5 × 2 cm, which showed similar histopathologic picture (Figure 1A, B). In addition, areas of bland necrosis containing apoptotic bodies became much more prominent (Figure 1C, D), neutrophils were not observed. Immunohistochemical stains were performed highlighting a large number of histiocytic cells CD68+ and plasmacytoid dendritic cells CD123+ (Figure 1E, F). The above description is characteristic of histiocytic necrotizing lymphadenitis which is an alternative term of this disease.

Based on histopathological findings, a diagnosis of KFD was established. Following excision, the patient's fever and malaise resolved. A positron emission tomography did not reveal any abnormal metabolic activity.

Discussion

Kikuchi-Fujimoto disease is an uncommon cause of lymphadenopathy in Europe, but it is more common in Asia [3–5]. The exact frequency is likely underestimated due to low clinical awareness and the lack of uniform diagnostic criteria [9]. The dis-

Table I. Laboratory investigation of the patient

PARAMETERS	ON ADMISSION	REFERENCE RANGE
White blood cell count (×10 ³ /μl)	2.14	4.16–11.48
Neutrophil (×10 ³ /μl)	0.88	1.90–8.0
Lymphocyte (×10 ³ /μl)	0.99	1.2–3.30
Eosinophil (×10 ³ /μl)	0.00	0.04–0.41
C-reactive protein [mg/l]	8.92	< 5.0
Partial thromboplastin time [s]	37.4	9.3–14.0
Prothrombin time [s]	15.5	25.4–36.9
Lactate dehydrogenase [U/l]	51.4	135–214
β-2-microglobulin [mg/l]	2.69	0.80–2.40
Virus antibody measurement		
Epstein-Barr virus viral capsid antigen IgG (S/CO)	62.86	≥ 1.0 reactive
Epstein-Barr virus viral capsid antigen IgM (S/CO)	0.38	≥ 1.0 reactive
Cytomegalovirus IgG (S/CO) [IU/ml]	237.0	≥ 1.0 reactive
Anti-parvovirus IgG antibodies [IU/ml]	> 150.0	≥ 2.5 reactive
HBsAg [IU/l]	30.3	< 10.0
HIV antigen-antibody combination test	Inactive	

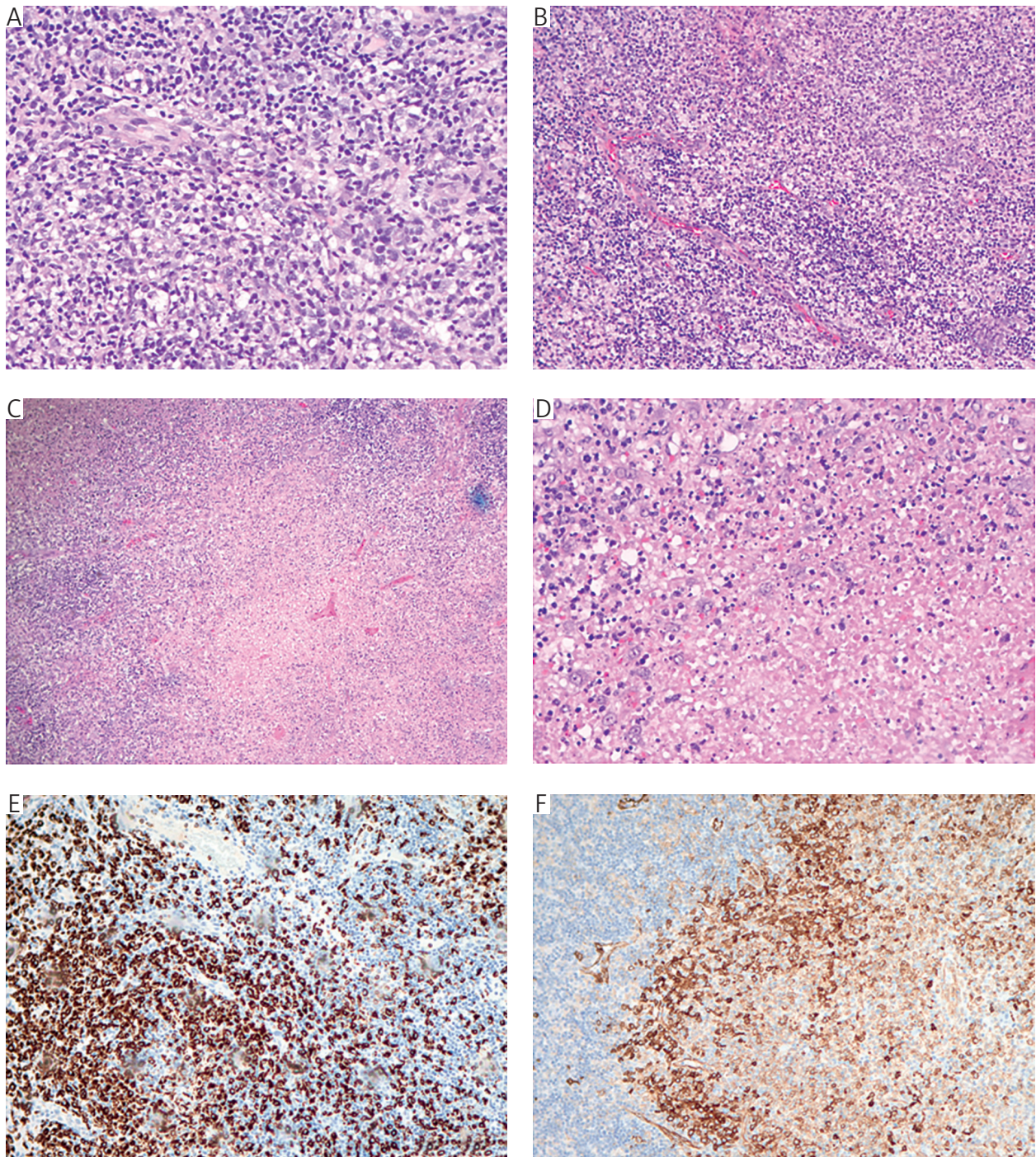


Figure 1. Histologic images showing effacement of lymph node architecture in core needle biopsy (A) and in excisional biopsy (B), areas of necrosis on low magnification (C) and high magnification (D) in excisional biopsy, CD68 immunohistochemical stain (E) and CD123 immunohistochemical stain (F) in excisional biopsy

ease primarily affects young adult women under 40 years old [6–9]. The suggested aetiology is infectious, involving various viral, bacterial, and parasitic pathogens or autoimmune factors [5, 11]. Kikuchi-Fujimoto disease is a regional, mild, and self-limiting form of lymphadenopathy [8]. These changes are most often localized in the neck, and less frequently in the axillary and supraclavicular regions. Lymph nodes are enlarged, tender, and painful, and

are usually unilateral. Occasionally, they may become hardened or adhere to surrounding tissue [4, 12, 13]. Symptoms typically resolve spontaneously within 1–4 months, and less commonly within 6 months [8, 9, 14–16]. Generalized lymphadenopathy is rare [8]. Most patients report a low-grade intermittent fever lasting approximately 1 to 4 weeks. Other symptoms may include malaise, headache, muscle pain, upper respiratory tract symptoms, oral ulcers,

and joint pain [7, 17]. These symptoms are less common and may include weight loss, nausea, vomiting, and night sweats. Cutaneous manifestations are uncommon and exhibit considerable morphological variability, most frequently involving the upper regions of the body. When present, the histopathological features of skin lesions closely resemble those observed in the affected lymph nodes, suggesting that heightened disease activity may elicit an apoptotic response in both tissues [18–21]. The differential diagnosis is broad and must include infectious, congenital, inflammatory and neoplastic aspects. Ongoing viral infections should be ruled out, with serological testing covering CMV, EBV, adenovirus, B19, coxsackievirus, HIV, *Borrelia*, *Mycoplasma*, *Toxoplasma gondii*, *Yersinia enterocolitica*, *Brucella*, and *Bartonella* [22–24]. Rare associations with KFD have been reported for vaccinations, including those for influenza, Japanese encephalitis, and HPV [9]. Recently, reports have also linked the disease to COVID-19 infection and SARS-CoV-2 vaccination [9, 14, 25–27]. However, it remains unclear whether this association is truly causal or merely coincidental. Autoimmune disorders such as systemic lupus erythematosus, Wegener granulomatosis, Sjögren syndrome, Graves' disease and Still disease have also been described in association with KFD [8]. However, these diseases should be viewed mainly in the context of differential diagnosis, rather than as direct causes [9, 10, 18, 28, 29]. Finally, neoplastic aetiologies should also be taken into account, including cervical metastases, primary malignancies of the upper gastrointestinal tract, or lymphoma.

In many patients, laboratory test results are normal. In the case of abnormalities in laboratory tests, an increase in erythrocyte sedimentation rate and CRP may be observed, along with mild anemia. The number of peripheral leukocytes, particularly granulocytes, decreases. One-third of patients show the presence of atypical lymphocytes in peripheral blood. Other possible abnormalities include elevated levels of aminotransferases and LDH in serum. In severe cases, thrombocytopenia and pancytopenia may occur [9, 10, 12, 13, 30].

The gold standard for diagnosis is surgical biopsy of the lymph node [8, 9]. Imaging, using US and/or computed tomography, should be part of the evaluation. Histopathological features suggestive of KFD typically show partially retained nodal architecture, with paracortical regions expanded by patchy fibrinoid necrosis, accompanied by prominent apoptosis and nuclear debris. These areas are infiltrated by aggregates of crescent-shaped histiocytes, activated T-lymphocytes (immunoblasts) and plasmacytoid monocytes. Typically, neutrophils and eosinophils are scarce [31–34]. The cellular infiltrate consists of CD68-positive plasmacytoid histiocytes and immunoblasts, mainly

of T-lymphocyte origin. The infiltrate is characterized by a predominance of CD8+ T-lymphocytes over CD4+ T-lymphocytes [4, 8, 30, 34, 35].

Symptomatic treatment with nonsteroidal anti-inflammatory drugs is used. In patients with severe, chronic, recurrent, or extensive disease, corticosteroids may be helpful. Hydroxychloroquine has been effectively used in some patients, especially in recurrent cases or those resistant to steroids, either as monotherapy or in combination with steroids. The patient's rapid improvement with corticosteroid therapy aligns with established treatment protocols for KFD, thus proving its efficacy. No benefit has been found from the use of antibiotics [11].

This case highlights the diagnostic challenges associated with KFD, which can mimic a variety of conditions. Recurrent fevers, significant weight loss, and a lack of response to conventional treatment prompted further diagnostic evaluation for neoplastic disease. Excisional biopsy established the diagnosis and differentiated it from other conditions.

Conclusions

This study aimed to present the case of a 36-year-old female with lymphadenopathy, leading to the diagnosis of KFD, a rare condition with an unclear aetiology. The patient lacked typical cervical lymph node enlargement but presented with enlarged axillary, supraclavicular, and infraclavicular lymph nodes, with histopathological examination confirming KFD. Laboratory tests revealed leukopenia, elevated CRP, and LDH levels. Diagnosis of KFD is often delayed due to nonspecific symptoms, highlighting the importance of histopathological analysis. It is essential to distinguish it from neoplastic diseases, as the treatment recommendations for these conditions differ significantly. Early recognition can improve prognosis, and symptomatic treatment can lead to rapid clinical improvement.

Disclosures

1. Institutional review board statement: Not applicable.
2. Assistance with the article: None.
3. Financial support and sponsorship: None.
4. Conflicts of interest: None.

References

1. Masab M, Surmachevska N, Farooq H. Kikuchi-Fujimoto Disease. In: StatPearls. Treasure Island (FL): StatPearls, 2025. Available from: <http://www.ncbi.nlm.nih.gov/books/NBK430830/> (accessed: 28.04.2025).
2. Kikuchi M. Lymphadenitis showing reticulum cell hyperplasia with nuclear debris and phagocytes. *Acta Hematol Jpn* 1972; 53: 379-380.
3. Pileri S, Kikuchi M, Helbron D, Lennert K. Histiocytic necrotizing lymphadenitis without granulocytic infiltration. *Virchows Arch Pathol Anat Histol* 1982; 395: 257-271.

4. Bosch X, Guilabert A, Miquel R, Campo E. Enigmatic Kikuchi-Fujimoto disease: a comprehensive review. *Am J Clin Pathol* 2004; 122: 141-152.
5. Pepe F, Disma S, Teodoro C, Pepe P, Magro G. Kikuchi-Fujimoto disease: a clinicopathologic update. *Pathologica* 2016; 108: 120-129.
6. Fujimoto Y. Cervical subacute necrotizing lymphadenitis. *Nai-ka* 1972; 30: 920-927.
7. Lin HC, Su CY, Huang CC, Hwang CF, Chien CY. Kikuchi's disease: a review and analysis of 61 cases. *Otolaryngol Head Neck Surg* 2003; 128: 650-653.
8. Perry AM, Choi SM. Kikuchi-Fujimoto disease: a review. *Arch Pathol Lab Med* 2018; 142: 1341-1346.
9. Mahajan VK, Sharma V, Sharma N, Rani R. Kikuchi-Fujimoto disease: a comprehensive review. *World J Clin Cases* 2023; 11: 3664-3679.
10. Kucukardali Y, Solmazgul E, Kunter E, Oncul O, Yildirim S, Kaplan M. Kikuchi-Fujimoto disease: analysis of 244 cases. *Clin Rheumatol* 2007; 26: 50-54.
11. Chong Y, Kang CS. Causative agents of Kikuchi-Fujimoto disease (histiocytic necrotizing lymphadenitis): a meta-analysis. *Int J Pediatr Otorhinolaryngol* 2014; 78: 1890-1897.
12. Ifeacho S, Aung T, Akinsola M. Kikuchi-Fujimoto disease: a case report and review of the literature. *Cases J* 2008; 1: 187.
13. Qadri F, Atkin GK, Thomas D, Das SK. Kikuchi's disease: an important cause of cervical lymphadenopathy. *Clin Med Lond Engl* 2007; 7: 82-84.
14. Al Ghadeer HA, AlKadhem SM, AlMajed MS, AlAmer HM, AlHabeeb JA, Alomran SH, et al. Kikuchi-Fujimoto disease following COVID-19. *Cureus* 2022; 14: e21049.
15. Deaver D, Horna P, Cualing H, Sokol L. Pathogenesis, diagnosis, and management of Kikuchi-Fujimoto disease. *Cancer Control J Moffitt Cancer Cent* 2014; 21: 313-321.
16. Rezaei K, Kuchipudi S, Chundi V, Ariga R, Loew J, Sha BE. Kikuchi-Fujimoto disease: hydroxychloroquine as a treatment. *Clin Infect Dis Off Publ Infect Dis Soc Am* 2004; 39: e124-126.
17. Lin HC, Su CY, Huang SC. Kikuchi's disease in Asian children. *Pediatrics* 2005; 115: e92-96.
18. Paradelo S, Lorenzo J, Martínez-Gómez W, Yebra-Pimentel T, Valbuena L, Fonseca E. Interface dermatitis in skin lesions of Kikuchi-Fujimoto's disease: a histopathological marker of evolution into systemic lupus erythematosus? *Lupus* 2008; 17: 1127-1135.
19. Kim KJ, Jee MS, Chang SE, Choi JH, Sung KJ, Moon KC, et al. Kikuchi-Fujimoto disease with papulopustular skin manifestations. *Clin Exp Dermatol* 2003; 28: 142-144.
20. Sumiyoshi Y, Kikuchi M, Takeshita M, Yoneda S, Kobari S, Ohshima K. Immunohistological study of skin involvement in Kikuchi's disease. *Virchows Arch B* 1992; 62: 263-269.
21. Yasukawa K, Matsumura T, Sato-Matsumura KC, Takahashi T, Fujioka Y, Kobayashi H, et al. Kikuchi's disease and the skin: case report and review of the literature. *Br J Dermatol* 2001; 144: 885-889.
22. Zhang WP, Wang JH, Wang WQ, Chen XQ, Wang Z, Li YF, et al. An association between parvovirus B19 and Kikuchi-Fujimoto disease. *Viral Immunol* 2007; 20: 421-428.
23. Sumiyoshi Y, Kikuchi M, Minematu T, Ohshima K, Takeshita M, Minamishima Y. Analysis of herpesvirus genomes in Kikuchi's disease. *Virchows Arch Int J Pathol* 1994; 424: 437-440.
24. Hudnall SD, Chen T, Amr S, Young KH, Henry K. Detection of human herpesvirus DNA in Kikuchi-Fujimoto disease and reactive lymphoid hyperplasia. *Int J Clin Exp Pathol* 2008; 1: 362-368.
25. Tan HM, Hue SSS, Wee A, See KC. Kikuchi-Fujimoto disease post COVID-19 vaccination: case report and review of literature. *Vaccines* 2021; 9: 1251.
26. Dagghi S, Belmoufid N, Rami A, Al Bouzidi A, Bouanani N. Kikuchi-Fujimoto's disease or histiocytic necrotizing lymphadenitis following mRNA COVID-19 vaccination: a rare case. *Cureus* 2022; 14: e24155.
27. Saito Y, Suwa Y, Kaneko Y, Tsujiwaki M, Odagawa Y. Kikuchi-Fujimoto disease following COVID-19 infection in a 7-year-old girl: a case report and literature review. *Cureus* 2022; 14: e26540.
28. Eisner MD, Amory J, Mullaney B, Tierney L, Browner WS. Necrotizing lymphadenitis associated with systemic lupus erythematosus. *Semin Arthritis Rheum* 1996; 26: 477-482.
29. Sharma V, Rankin R. Fatal Kikuchi-like lymphadenitis associated with connective tissue disease: a report of two cases and review of the literature. *SpringerPlus* 2015; 4: 167.
30. Pileri SA, Facchetti F, Ascani S, Sabattini E, Poggi S, Piccioli M, et al. Myeloperoxidase expression by histiocytes in Kikuchi's and Kikuchi-like lymphadenopathy. *Am J Pathol* 2001; 159: 915-924.
31. Tong K. A Clinicopathologic study of 79 cases with an analysis of histologic subtypes, immunohistology, and DNA ploidy. *Am J Surg Pathol* 1995; 19: 798-809.
32. Spies J, Foucar K, Thompson CT, le Boit PE. The histopathology of cutaneous lesions of Kikuchi's disease (necrotizing lymphadenitis): a report of five cases. *Am J Surg Pathol* 1999; 23: 1040-1047.
33. Lin H, Su C, Huang C, Hwang C, Chien C. Kikuchi's disease: a review and analysis of 61 cases. *Otolaryngol Neck Surg* 2003; 128: 650-653.
34. Hutchinson CB, Wang E. Kikuchi-Fujimoto disease. *Arch Pathol Lab Med* 2010; 134: 289-293.
35. Mrówka-Kata K, Kata D, Kyrzcz-Krzemień S, Helbig G. Kikuchi-Fujimoto and Kimura diseases: the selected, rare causes of neck lymphadenopathy. *Eur Arch Otorhinolaryngol* 2010; 267: 5-11.

Address for correspondence

Jakub Stanek
 2nd Department of Surgical Oncology
 Copernicus Memorial Multi-Specialist Oncology
 and Trauma Center
 62 Pabianicka St.
 93-513 Lodz, Poland
 e-mail: jakubstanek22@gmail.com