Case report

The inflammatory odontogenic cyst known as a paradental cyst

Halil Anlar[1], Zuhal Ovuz[2]

[1]Department of Oral and Maxillofacial Surgery, Faculty of Dentistry, Çankırı Karatekin University, Çankırı, Turkey
[2]Department of Oral and Maxillofacial Radiology, Faculty of Dentistry, Çankırı Karatekin University, Çankırı, Turkey

A paradental cyst (PC) is an inflammatory odontogenic cyst typically found on the buccal and distal surfaces of slightly impacted lower third molars. The inflammatory pathway is associated with a history of pericoronitis, which originates from an inflammatory process in the periodontal pocket. The proliferation of Malassez epithelial rests due to inflammation is considered the primary etiology of these cysts. Due to limited clinical data, PC is often underreported and may be misdiagnosed as an inflamed dental follicle, lateral radicular cyst, pericoronitis, or dentigerous cyst. This study presents the case of a 21-year-old male patient who was referred to the oral and maxillofacial radiology department with a six-month history of pain on the distal surface of his lower third molars. The patient was subsequently referred to the maxillofacial surgery clinic for tooth extraction. Paradental cyst diagnosis was confirmed *via* histopathological analysis. Proper clinical, radiological, and histopathological evaluations are essential for accurately distinguishing inflammatory PCs from other odontogenic cysts.

Key words: inflammatory cysts, paradental cyst, pathology.

Introduction

According to the World Health Organization (WHO) classification, paradental cysts (PC) develop from an inflammatory process within the periodontal pocket, forming on the lateral aspect of the root near the cervical margin [1]. A specific variant of PC is associated with a history of periodontitis and typically appears on the buccal and distal surfaces of developing mandibular molars, particularly the third molars. Paradental cysts are relatively rare in clinical practice, with an incidence of 0.9–4.7% [2]. However, their actual prevalence may be underestimated because of their ambiguous clinical presentation [1]. Patients with PCs often experience pain and gingival swelling due to recurrent diseases. Radiographic examination may reveal cystic lesions encasing the roots or located on the distal aspect of affected teeth. Accurate diagnosis requires comprehensive clinical, radiological, and pathological evaluations [3]. Despite their occurrence in clinical practice, PCs remain under-recognized by many clinicians. Furthermore, there is an ongoing debate regarding their etiology, and consensus on optimal treatment strategies has yet to be established [4].

Case report

A 21-year-old male patient presented to the maxillofacial radiology clinic with complaints of pain associated with a partially impacted third molar. Clinical evaluation indicated that the patient had no systemic diseases, was not on any medication, and smoked. Intraoral examination revealed that the distal aspect of the lower left third molar was partially erupted beneath the mucosa. The mucosa distal to the third molar exhibited erythema and swelling. The patient also reported symptoms of a sore throat and the presence of a salty fluid discharge. Cone-beam computed tomography was used for radiological evaluation.

This is an Open Access journal, all articles are distributed under the terms of the Creative Commons Attribution-NonCommercial-ShareAlike 4.0 International (CC BY-NC-SA 4.0) License (http://creativecommons.org/licenses/by-nc-sa/4.0/)

© Polish Society of Pathologists

Radiological examination

Cone-beam computed tomography imaging revealed a well-defined, corticated, radiolucent lesion measuring 14 × 26 mm, encompassing the crown and root of the distal aspect of the lower left third molar (Figure 1). The lesion had a close anatomical relationship with the mandibular canal. In the ramus region, the mandibular canal was observed to course lingual to the lesion before passing through it (Figure 2). The distal root of the third molar was in contact with the lesion; however, there was no evidence of root resorption. No signs of expansion or disruption were detected in the buccal or lingual cortical plates of the mandible.

Surgical examination

Owing to the lesion's close anatomical proximity to the inferior alveolar canal, an initial decompression procedure was performed to reduce its size before enucleation. Under local anesthesia, a crestal incision was made, and a full-thickness mucoperiosteal flap was elevated. The impacted third molar was extracted, and a drainage system was installed at the lesion site. The surgical area was sutured. The drain was periodically replaced, and postoperative management included regular irrigation of the cystic cavity and maintenance of optimal oral hygiene. During follow-up examinations, the lesion demonstrated progressive regression in size and gradual displacement from the mandibular canal. Enucleation was performed six months after the initial procedure. A one-year postoperative evaluation revealed significant ossification at the lesion site, with no reported complications or symptoms, indicating successful healing and favorable treatment outcomes.

Histopathological examination

Histopathological examination revealed a cyst wall composed of non-keratinized, spongiotic, stratified squamous epithelium. The observations included epithelial hyperplasia and leukocyte exocytosis. The fibro vascular connective tissue exhibited regions of dystrophic calcification, hemorrhage, hyperemic blood vessels, and infiltration by active and chronic inflammatory cells. These findings align with the characteristics of inflammatory PC (Figure 3).

Discussion

Chrcanovic *et al.* [3] noted that a PC has been referred to by various terms, such as "inflammatory collateral cyst," "mandibular infected buccal cyst," "mandibular buccal bifurcation cyst," "inflammatory lateral periodontal cyst," and "inflammatory PC" [4, 5]. Paradental cysts are considered an uncommon type of odontogenic cyst [6]. In 1992, the WHO included PC in the classification of odontogenic tumor histological types [1]. Its relatively recent classification may contribute to its under-recognition. Additionally, this lesion is often misdiagnosed or underdiagnosed as a lateral radicular cyst, dentigerous cyst, odontogenic keratocyst, pericoronitis, lateral periodontal cyst, or other inflammatory conditions related to the dental follicle [6]. Li *et al.* [8] suggested the following diagnostic criteria for PCs:

- the affected tooth should be partially or fully erupted and in direct contact with the cyst,
- the associated tooth should be vital,



Figure 1. Cone-beam computed tomography image showing a well-defined, corticated radiolucent lesion (14 × 26 mm) involving the crown and distal root surface of the left mandibular third molar



Figure 2. Cone-beam computed tomography sections showing the close relationship between the lesion and the mandibular canal, which courses lingual to the lesion before passing through it in the ramus region

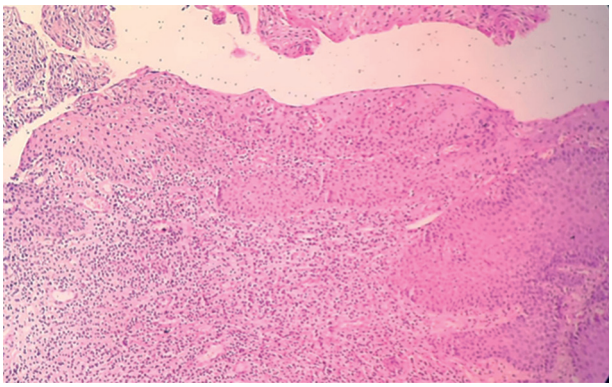

Figure 3. Histopathological view of the lesion showing fibrovascular connective tissue with dystrophic calcification, hemorrhage, hyperemic blood vessels, and active and chronic inflammatory cell infiltration, consistent with an inflammatory paradental cyst

- a deep periodontal pocket may be present on the side where the cyst is attached,
- radiographic imaging should show the cyst near the cemento-enamel junction with a well-defined margin,
- histopathological examination should confirm a nonspecific inflammatory odontogenic cyst.

The inflammatory nature of PCs is supported by histological findings, including odontogenic epithelial proliferation, inflammatory cell infiltration, and occasional hyaline changes in the blood vessel walls [5]. However, the precise pathogenesis of PC remains unknown. Fowler and Brannon discussed the similarities between PC and lateral periodontal cysts in terms of clinical and radiographic appearance, noting that the latter has a developmental rather than inflammatory origin. They also speculated that PC might represent a variant of dentigerous cysts or originate from an obstructed periodontal pocket [9]. A review of the literature indicates that Hofarth first reported numerous cases of jaw cysts on the distal aspect of mandibular third molars presenting with clinical signs of pericoronitis in 1930. He referred to these lesions as "marginal wisdom tooth cysts." Mufeed *et al*. [10] later emphasized that the clinical, radiological, and histological criteria for diagnosing PC align with Hofarth's description. In the present case, the cyst was located on the lateral aspect and crown area of an impacted tooth. The involved teeth were vital, effectively ruling out the possibility of a radicular cyst at the site.

Colgan *et al*. [6] highlighted the importance of a preserved follicular space, which remains unaffected by cyst formation, as a distinctive radiographic feature known as "Colgan's sign." This feature is a valuable diagnostic tool for distinguishing PCs from dentigerous cysts. Conversely, Chrcanovic *et al*. [3] observed that although inflammatory collateral cysts, PCs, and mandibular infected buccal cysts share the same etiology and histology, their clinical and radiological differences may stem from variations in the affected tooth type and eruption status of the affected teeth. Despite these discussions, ambiguity remains regarding the relationship between these three entities, as they are often considered identical lesions, regardless of location. Magnusson *et al.* [4] conducted a clinicopathological study of 26 cases of PCs, revealing histopathological features such as non-keratinized stratified squamous epithelium infiltrated by neutrophils. In most cases, significant epithelial hyperplasia was observed, with mixed infiltration of the connective tissue wall by neutrophils, lymphocytes, and plasma cells. These findings are consistent with our observations. In our case, we noted mixed inflammatory cell infiltration in the connective tissue and localized hyperplasia in the spongiotic stratified squamous epithelium. Neither keratinization of the epithelial surface nor cystic content was observed in the specimen. Localized ossification and dystrophic calcification have also been observed.

Marsupialization, initially introduced by Partsch as a treatment for cystic lesions, involves creating a surgical window to establish communication between the lesion and oral or paranasal cavities [11]. This technique reduces internal hydrostatic pressure, facilitating continuous cystic fluid drainage and promoting lesion shrinkage, bone regeneration, and metaplasia of pathological tissues, ultimately leading to improved outcomes [12]. The successful management of large odontogenic cysts through initial marsupialization followed by second-stage enucleation and curettage has been well documented [13–15]. In cases where lesions reach considerable sizes, as seen in the present case, a two-stage approach helps preserve critical anatomical structures, thereby minimizing treatment-related complications and reducing the need for extensive surgical reconstruction of the affected area. Furthermore, this strategy aids in maintaining the integrity of the inferior alveolar nerve, mandibular contour, and normal facial development, while also lowering the risk of mandibular fractures and cyst recurrence. Consequently, it enhances the patient's overall quality of life [6]. Vedtofte *et al*. [2] suggested that PCs originate in association with pericoronitis, a view we support, given the history of pericoronitis in our case [2]. The preferred treatment approach involves complete removal of the cystic lesion along with extraction of the affected tooth in cases involving the third molars. However, for first and second molars, preservation of the tooth is recommended whenever possible [9]. In our case, the treatment consisted of tooth extraction and enucleation of the lesion.

Conclusions

One of the distinguishing characteristics of PC, as observed clinically, is its association with mandibular molars, indicating the limited distribution of this lesion, which is characterized by well-defined radiolucency on radiographs. The controversies surrounding the various terminologies used for this entity stem from its diverse clinical presentations and have consistently been debated in the literature. Given the absence of a specific histopathological or clinical feature to describe this lesion, a combined clinicopathological assessment is crucial to achieve a definitive diagnosis of PC.

Disclosures

1. Institutional review board statement: Not applicable.
2. Assistance with the article: None.
3. Financial support and sponsorship: None.
4. Conflicts of interest: None.

References

1. Kramer IRH, Pindborg JJ, Shear M. The WHO histological typing of odontogenic tumours. A commentary on the second edition. Cancer 1992; 70: 2988-2994.
2. Vedtofte P, Praetorius F. The inflammatory paradental cyst. Oral Surg Oral Med Oral Pathol 1989; 68: 182-188.
3. Chrcanovic BR, Reis BMMV, Freire-Maia B. Paradental (mandibular inflammatory buccal) cyst. Head Neck Pathol 2011; 5: 159-164.
4. Magnusson B, Borrman H. The paradental cyst a clinicopathologic study of 26 cases. Swed Dent J 1995; 19: 1-7.
5. Borgonovo A, Reo P, Grossi G, Maiorana C. Paradental cyst of the first molar: Report of a rare case with bilateral presentation and review of the literature. J Indian Soc Pedod Prev Dent 2012; 30: 343-348.
6. Colgan CM, Henry J, Napier SS, Cowan CG. Paradental cysts: a role for food impaction in the pathogenesis? A review of cases from Northern Ireland. Br J Oral Maxillofac Surg 2002; 40: 163-168.
7. Ackermann G, Cohen MA, Altini M. The paradental cyst: a clinicopathologic study of 50 cases. Oral Surg Oral Med Oral Pathol 1987; 64: 308-312.
8. Li P, Zhao Y, You Y, Lin L, Yu D, Zhao W. Current perspectives on paradental cyst: a literature review. Dent J 2023; 11: 281.
9. Fowler CB, Brannon RB. The paradental cyst: a clinicopathologic study of six new cases and review of the literature. J Oral Maxillofac Surg 1989; 47: 243-248.
10. Mufeed A, Chatra L, Shenai P. Diagnostic features of the paradental cyst and report of a case. Dentomaxillofacial Radiol 2009; 38: 125-126.
11. Souza LN, Souza ACRA, Gomes CC, Motta Loyola A, Durighetto AF Jr, Gomez RS, et al. Conservative treatment of calcifying odontogenic cyst: report of 3 cases. J Oral Maxillofac Surg 2007; 65: 2353-2356.
12. Emam HA, Smith J, Briody A, Jatana CA. Tube decompression for staged treatment of a calcifying odontogenic cyst – a case report. J Oral Maxillofac Surg 2017; 75: 1915-1920.
13. Borgonovo AE, Di Lascia S, Grossi G, Maiorana C. Two-stage treatment protocol of keratocystic odontogenic tumour in young patients with Gorlin-Goltz syndrome: marsupialization and later enucleation with peripheral ostectomy. A 5-year-follow-up experience. Int J Pediatr Otorhinolaryngol 2011; 75: 1565-1571.
14. De Moraes ATL, Soares HA, Viana Pinheiro JDJ, Ribeiro Ribeiro AL. Marsupialization before enucleation as a treatment strategy for a large calcifying odontogenic cyst: case report. Int J Surg Case Rep 2020; 67: 239-244.
15. Pinto GNDS, Figueira JA, Gonçales ES, Sant'Ana E, Tolentino E. Marsupialização como tratamento definitivo de cistos odontogênicos: relato de dois casos. Rev Fac Odontol – UPF 2016; 20.

Address for correspondence

Halil Anlar, PhD
Department of Oral and Maxillofacial Surgery
Faculty of Dentistry
Çankırı Karatekin University
Uluyazı, 18000 Çankırı, Turkey
Phone: 90 505 612 26 92
e-mail: halilanlar@hotmail.com